

**CORSO PRATICO
DI
DIAGNOSTICA MAMMOGRAFICA
INTEGRATA PER RADIOLOGI**

M. Tonegutti

Peschiera del Garda 2009

CASA DI CURA PRIVATA Dr. PEDERZOLI s.p.a.

GISMA



APPROCCIO SISTEMATICO ALLA ANALISI DEI REPERTI

Lo screening non è la diagnosi!

LETTURA SISTEMATICA DEI MAMMOGRAMMI

requisiti fondamentali

- **Tecnica radiografica eccellente**
- **Condizioni di visione ottimali**
- **Analisi comparativa**

SCREENING MAMMOGRAFICO

modalità di approfondimento

- **Proiezioni supplementari**
- **Compressione mirata**
- **Ingrandimento diretto**
- **Ecografia**
- **Procedure interventistiche**

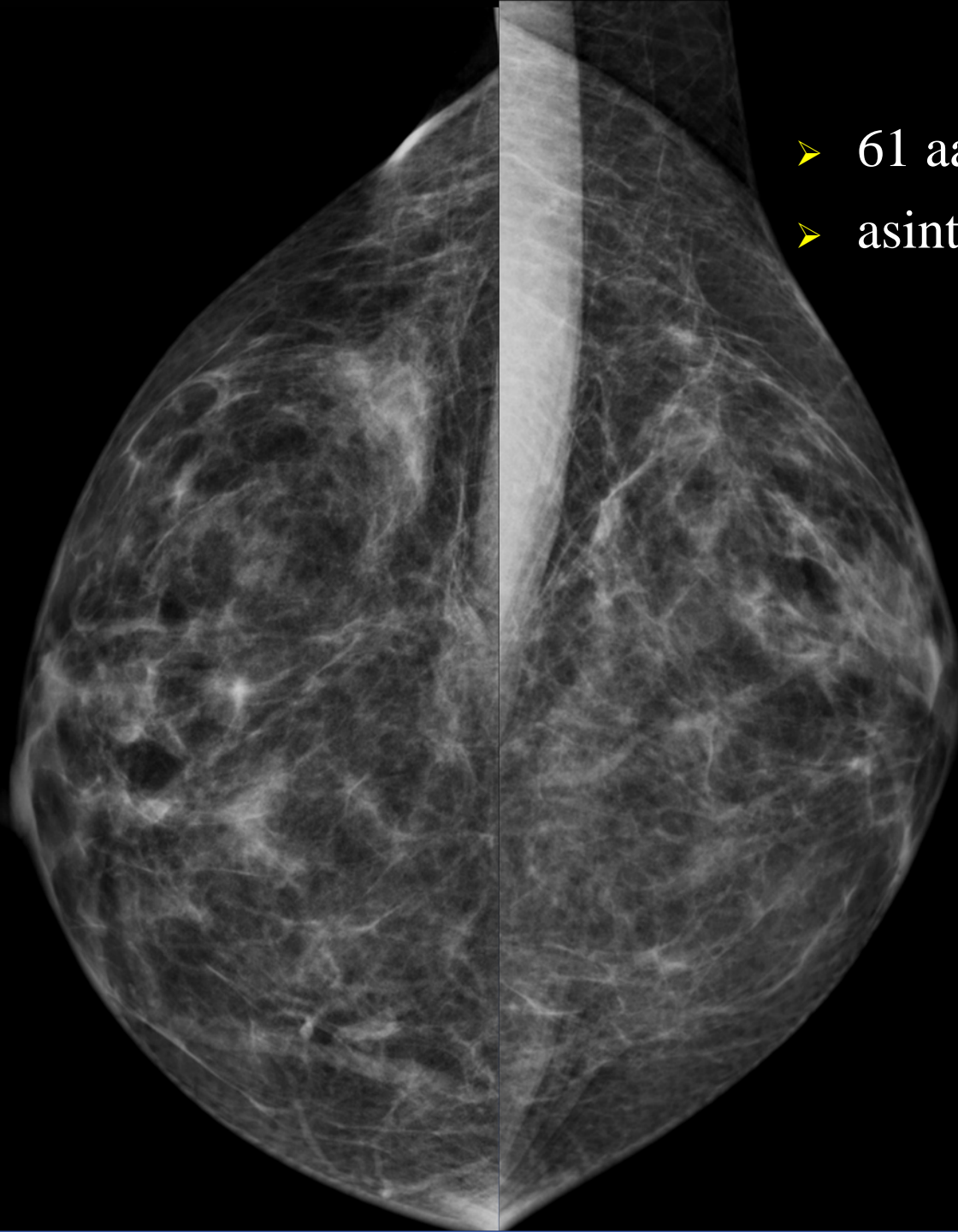ANALISI DEI MAMMOGRAMMI

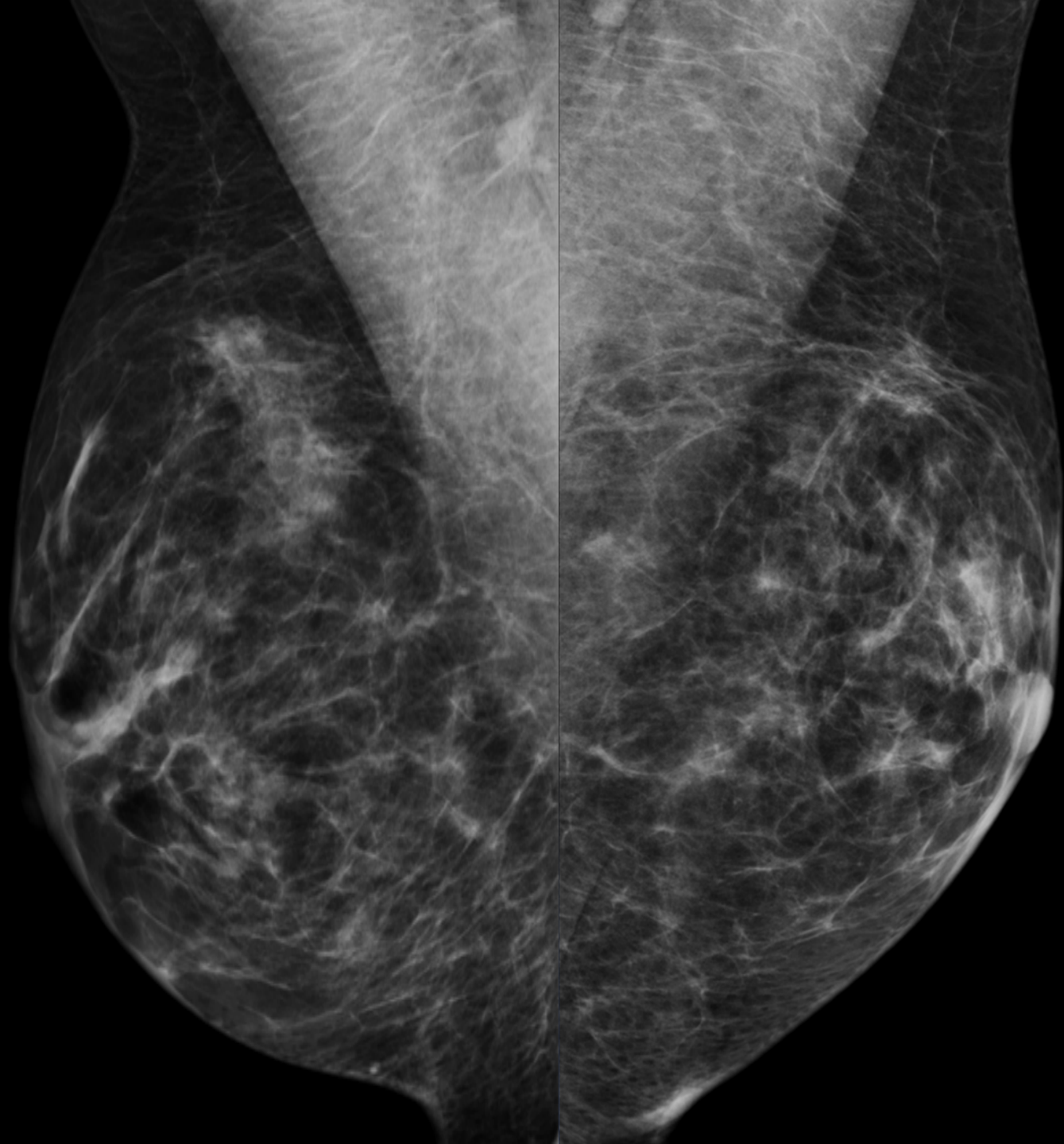parametri di valutazione

- **Opacità asimmetriche**
- **Alterazioni della armonia strutturale**
- **Micro - calcificazioni**
- **Anormalità nella zona del capezzolo o retroareolare**

CASO 1

- 61 aa
- asintomatica





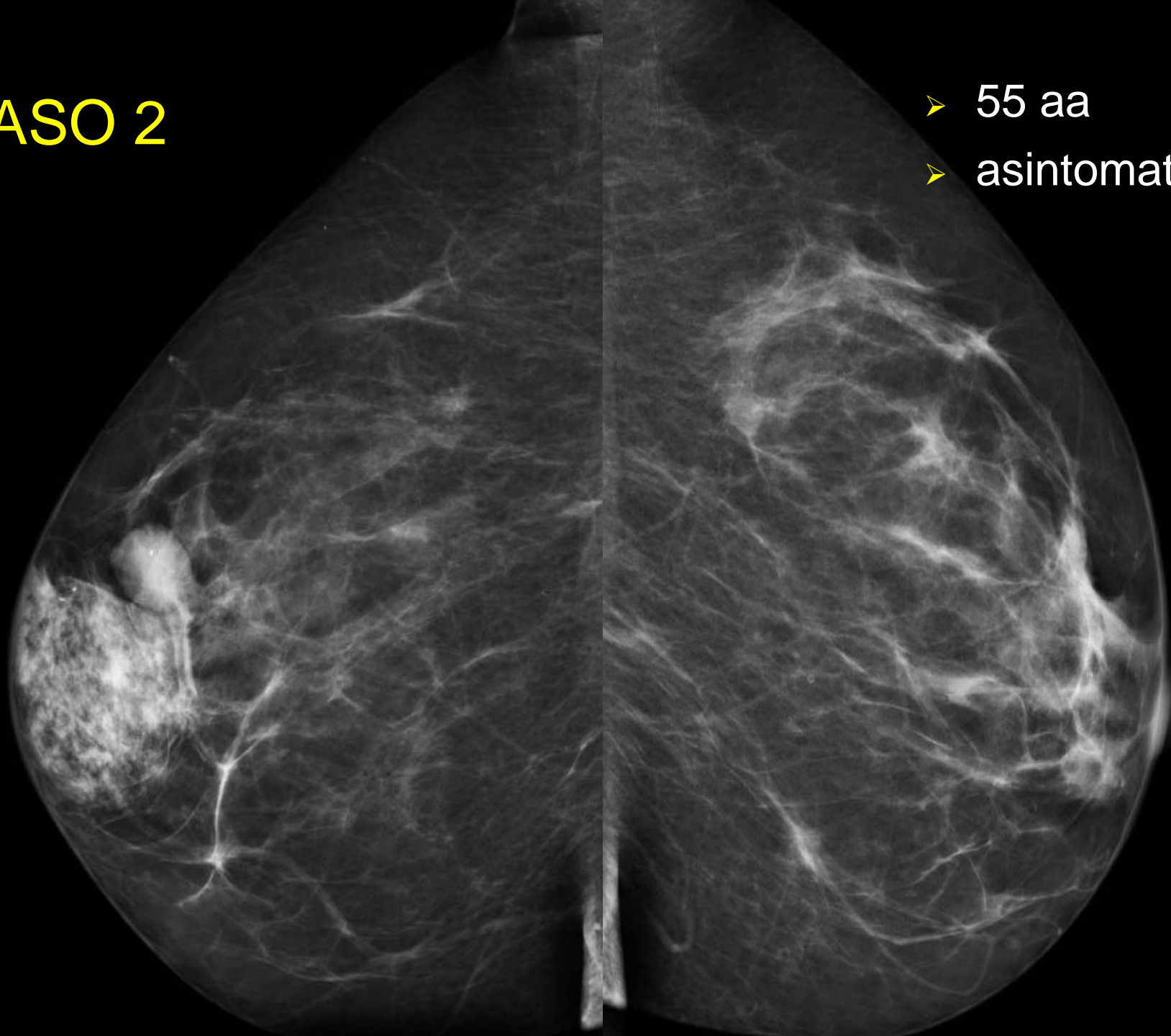
Approfondiamo?

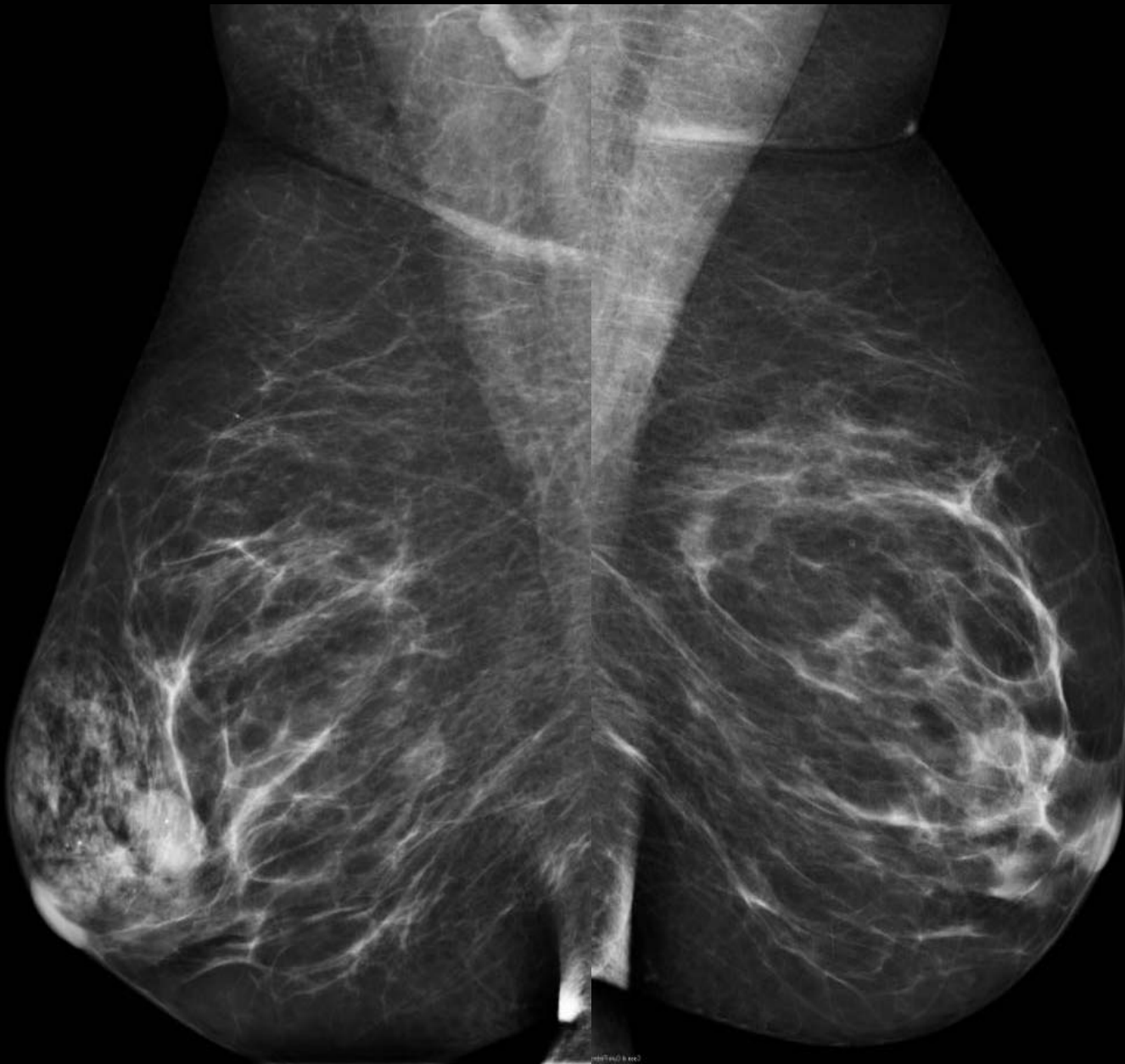
A) SI

B) NO

CASO 2

- 55 aa
- asintomatica





Approfondiamo?

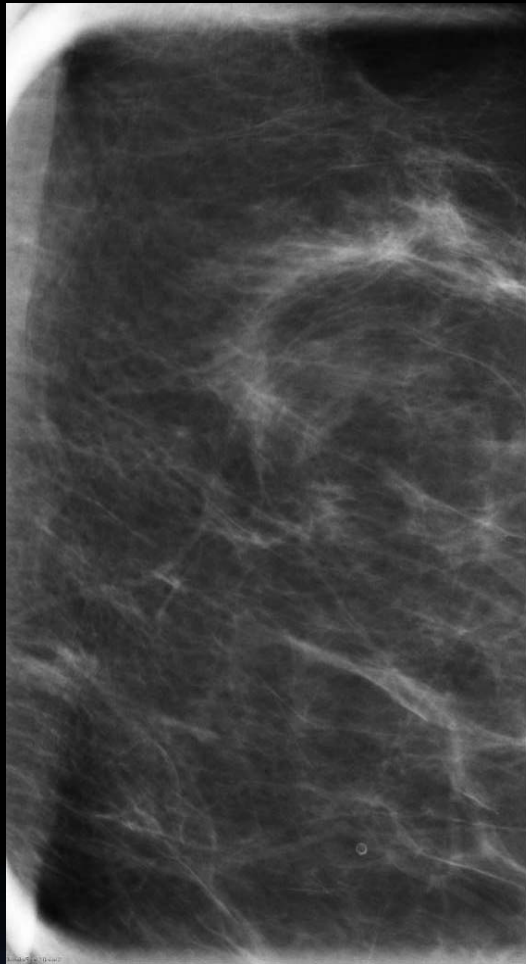
- A) Si
- B) NO

Dove?

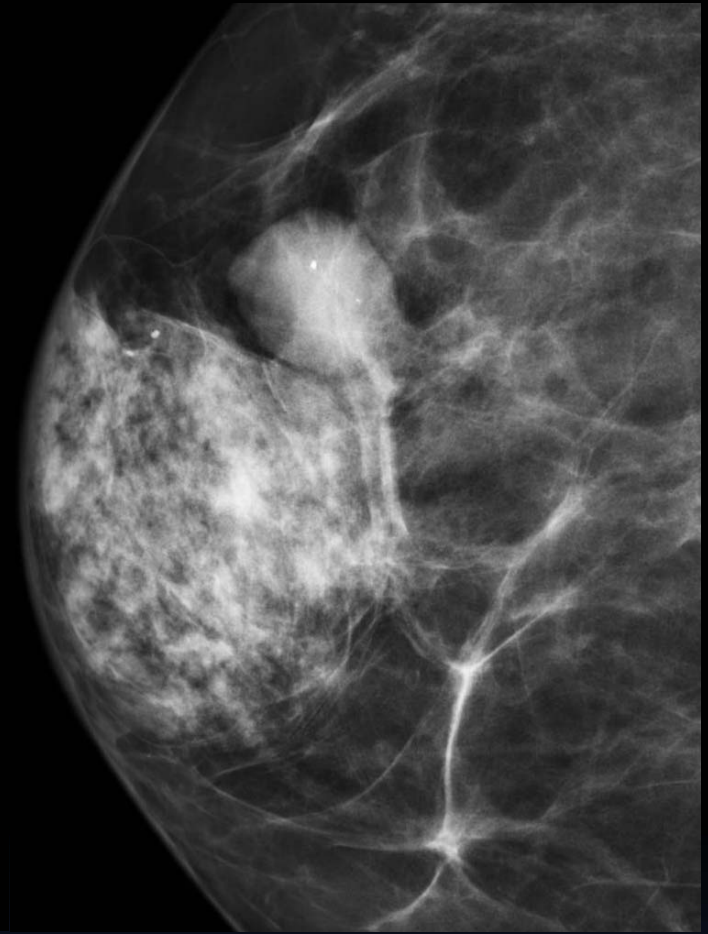
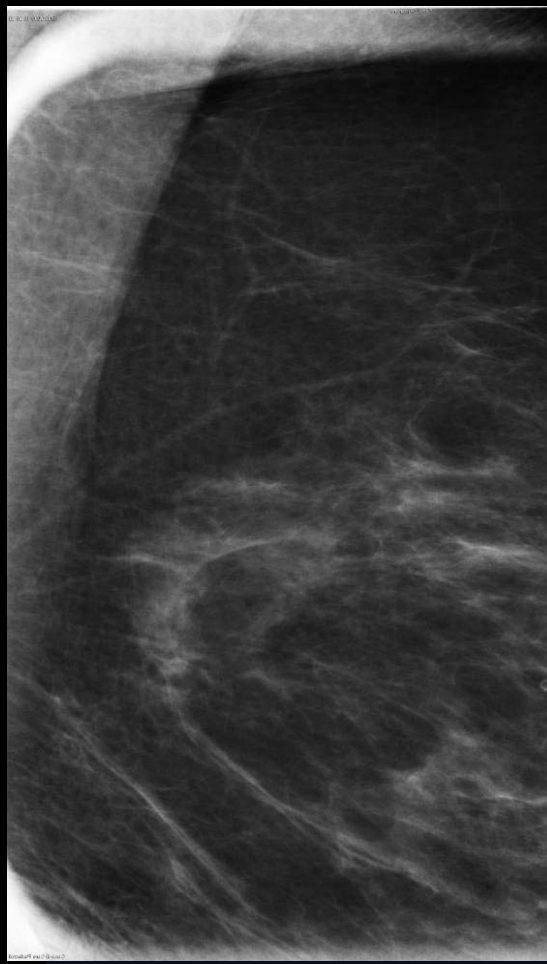
- A) DX
- B) SX

Come?

- A) Compressione mirata
- B) Ingrandimento
- C) Rx supplementen
- D) Ecografia
- E) A + B

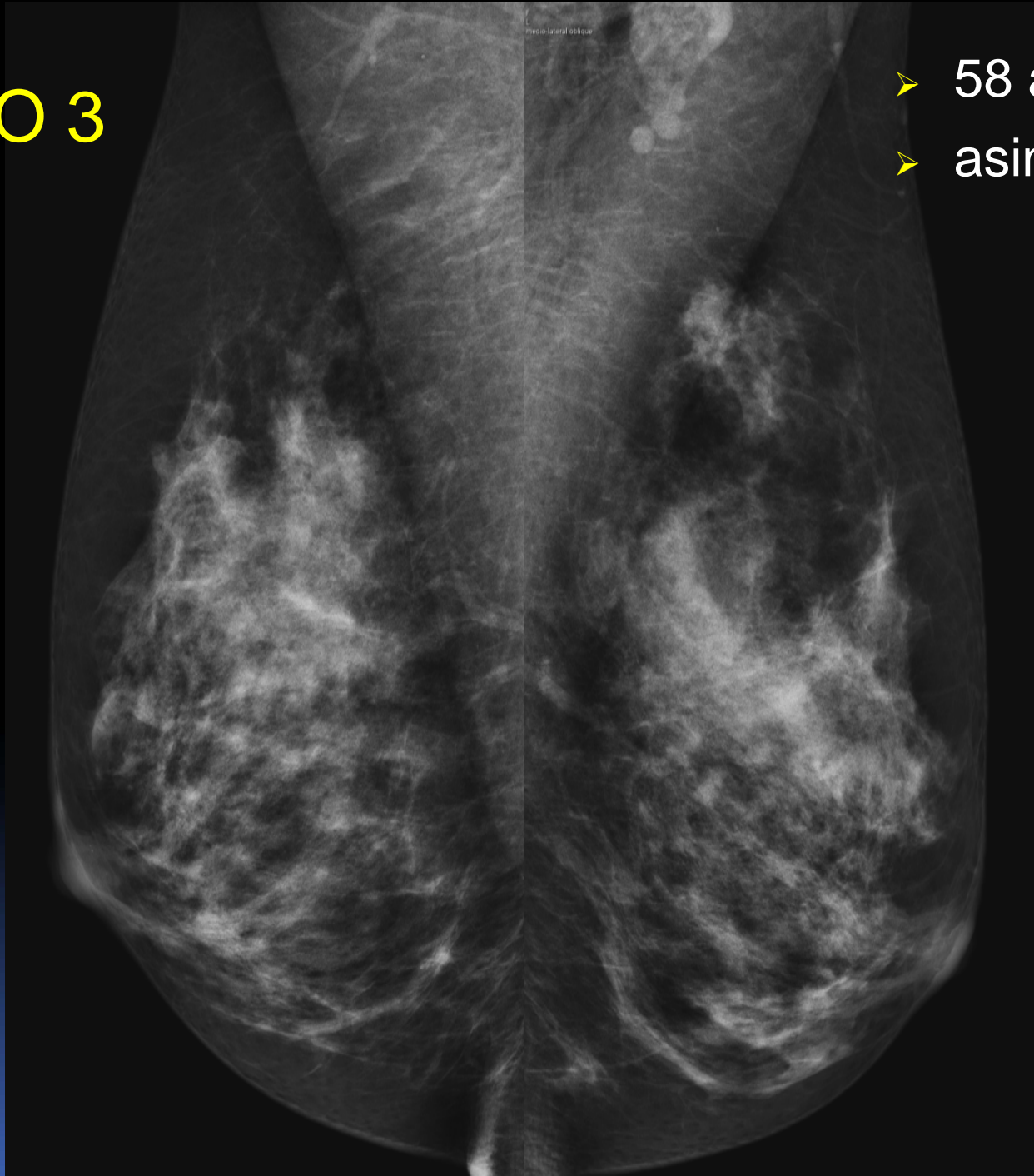


Compression mirata a sx

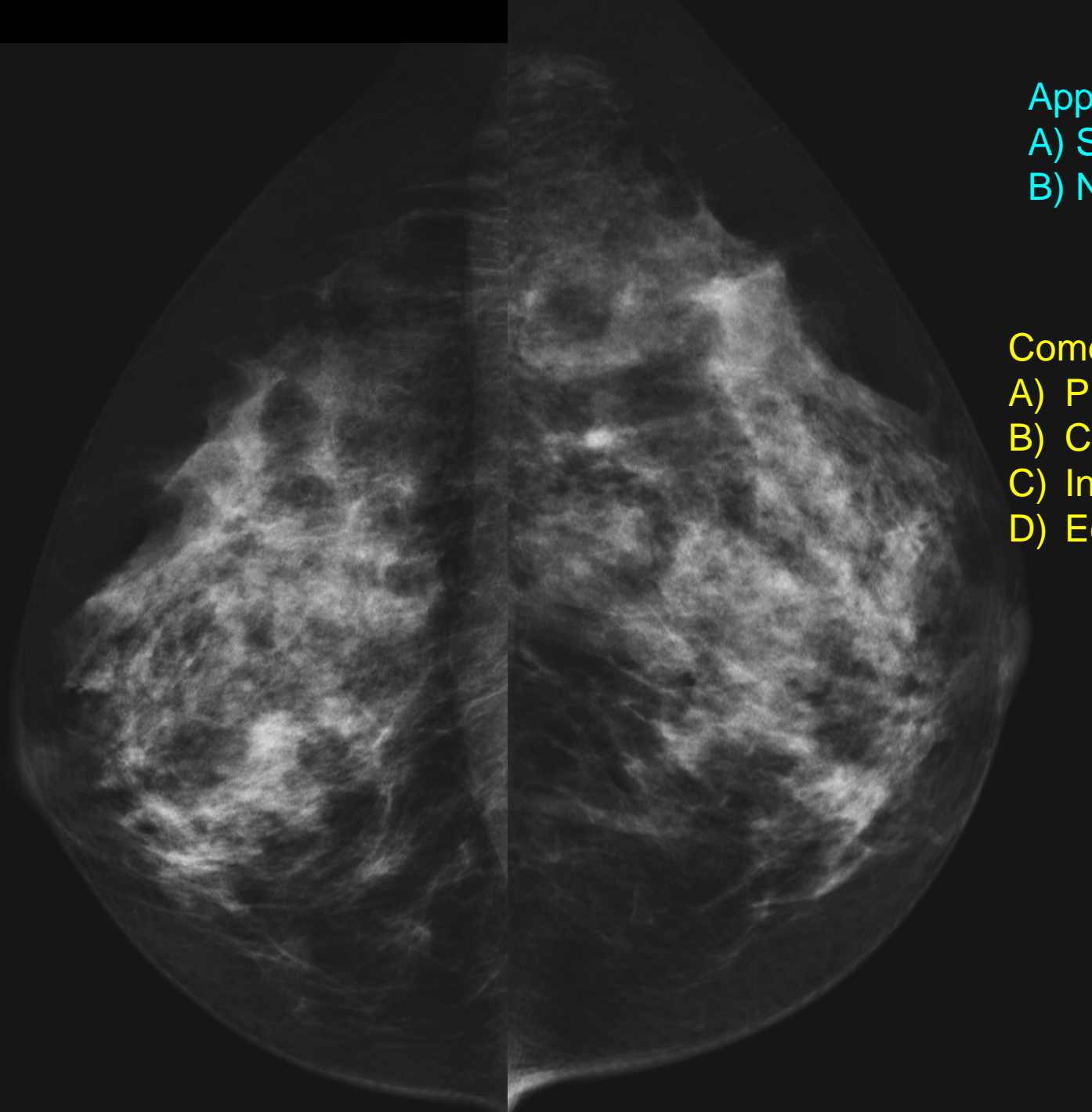


Ingrandimento a dx

CASO 3



- 58 aa
- asintomatica

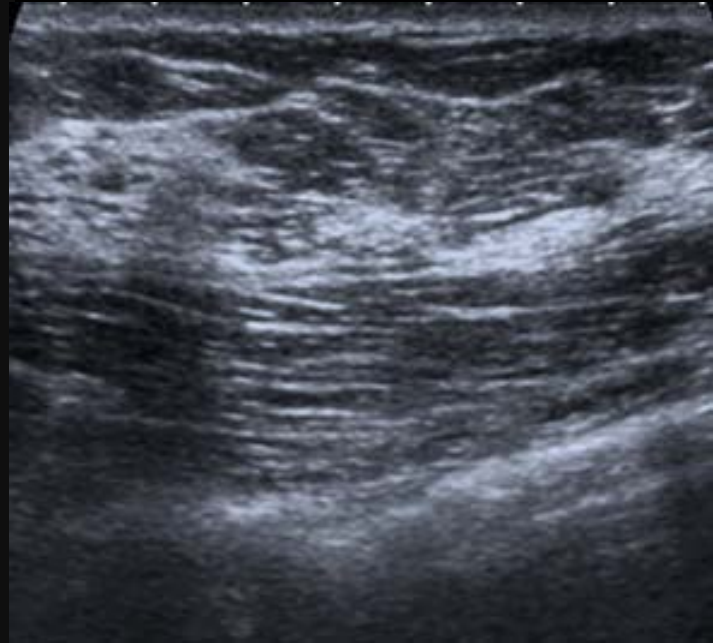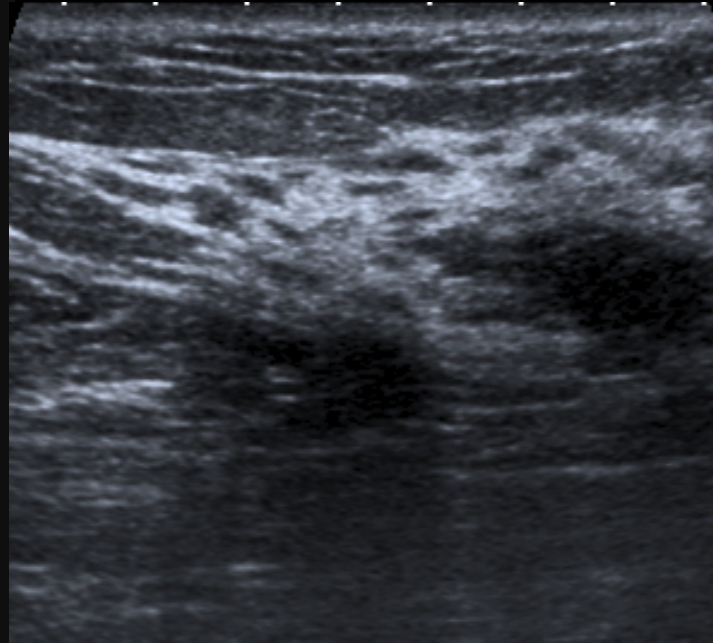
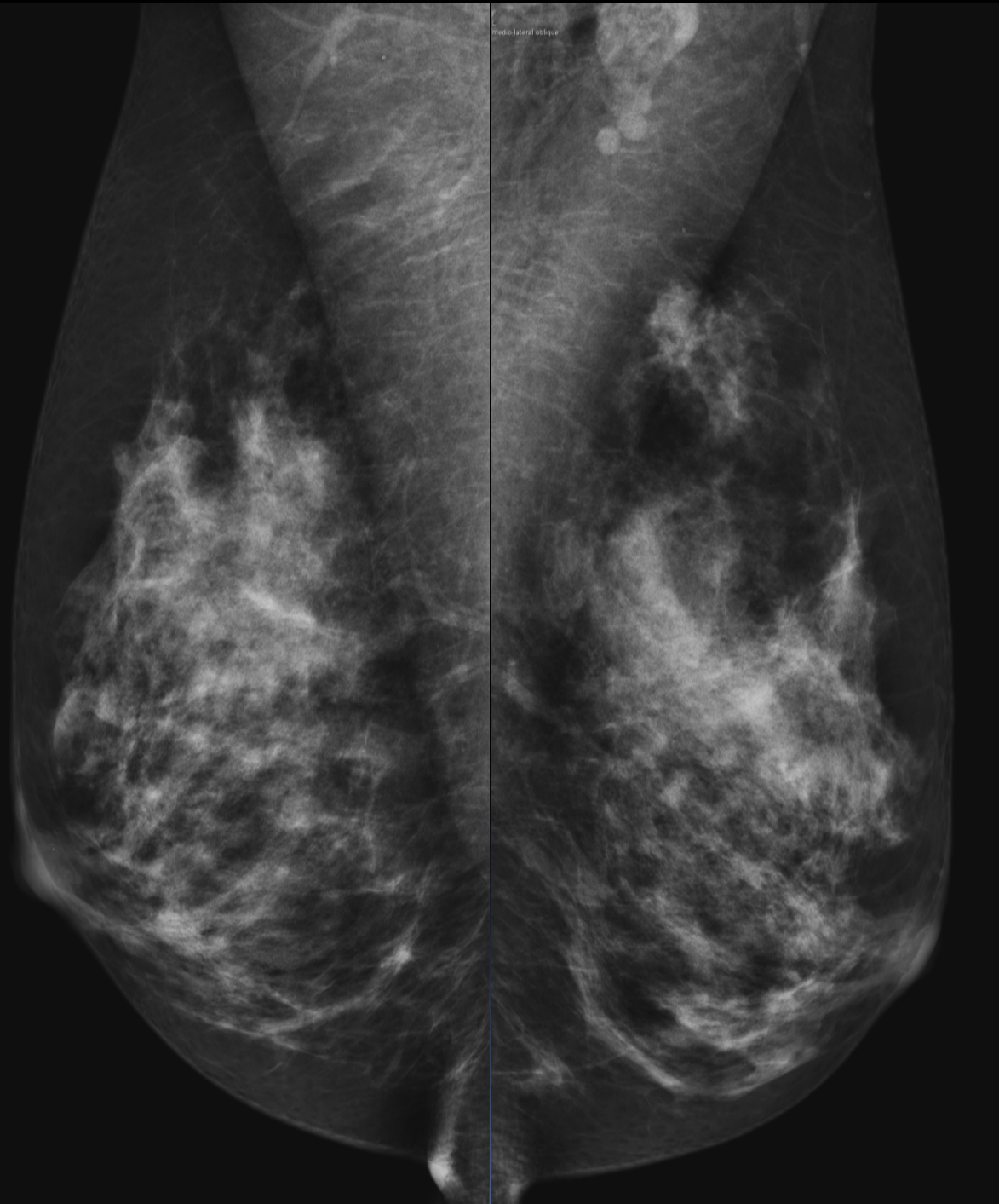


Approfondiamo?

- A) SI
- B) NO

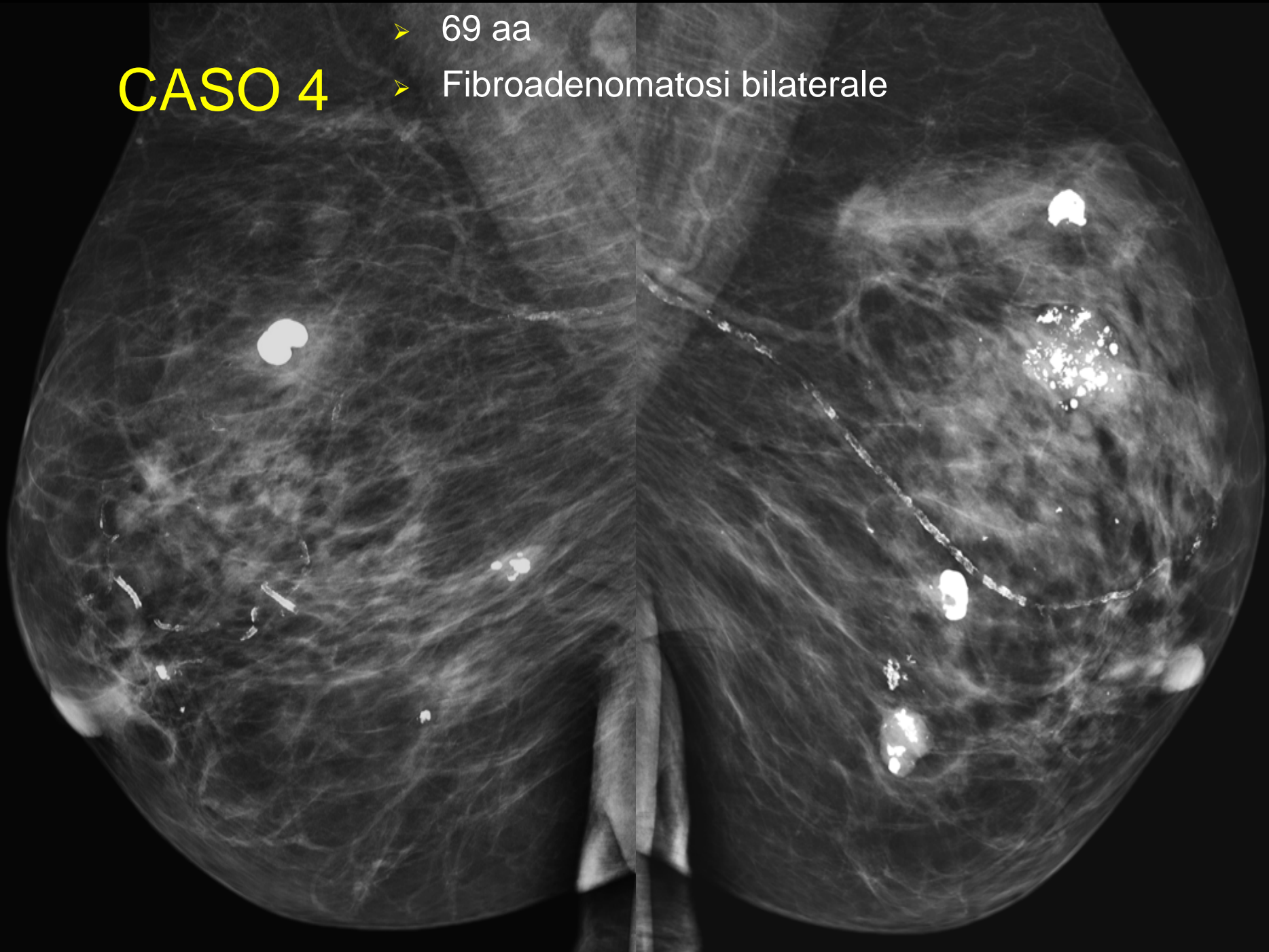
Come?

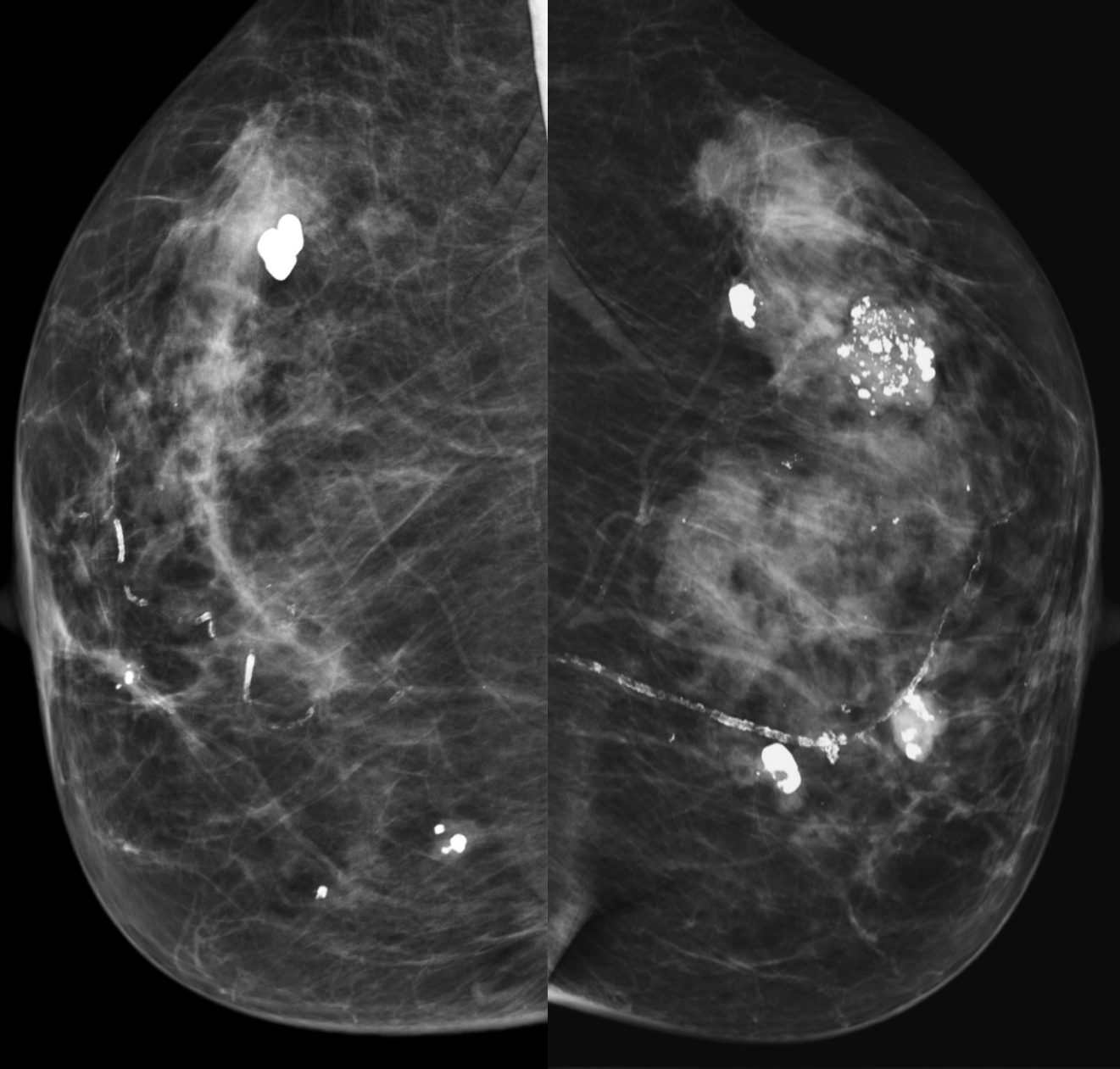
- A) Proiez. supplementare
- B) Compressione mirata
- C) Ingrandimento
- D) Ecografia



CASO 4

- 69 aa
- Fibroadenomatosi bilaterale





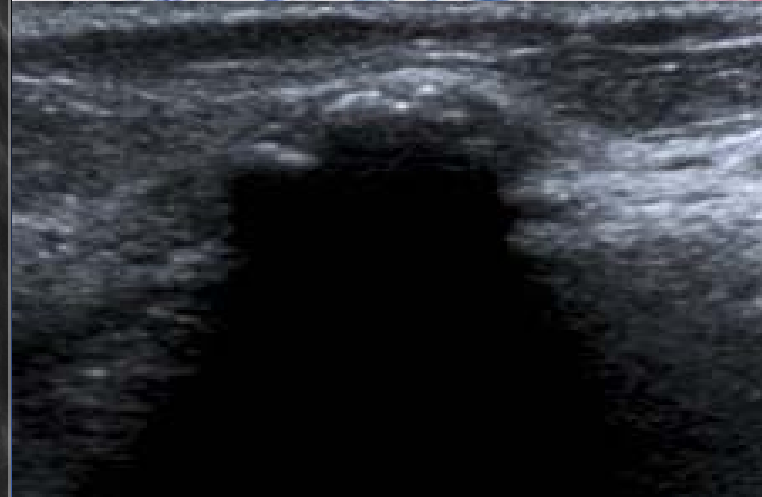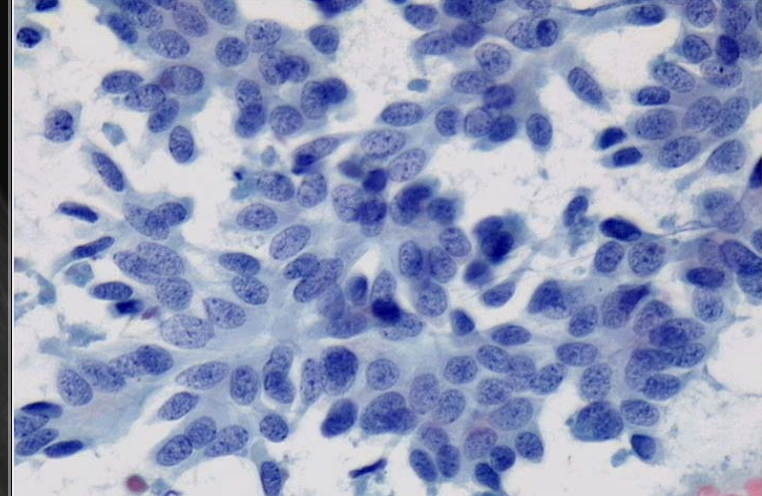
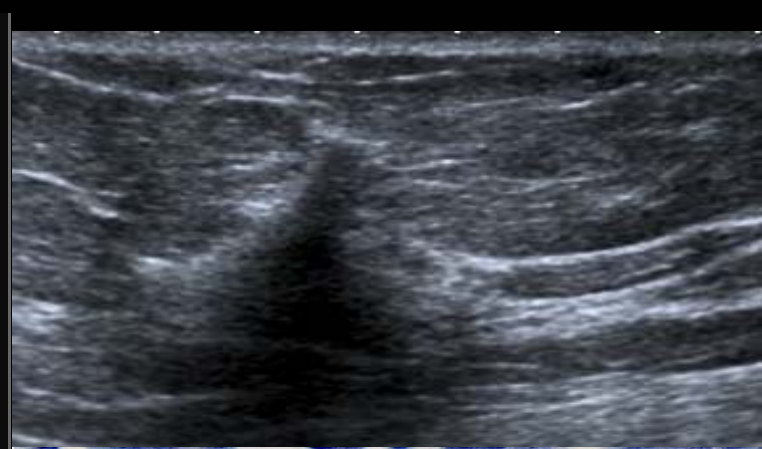
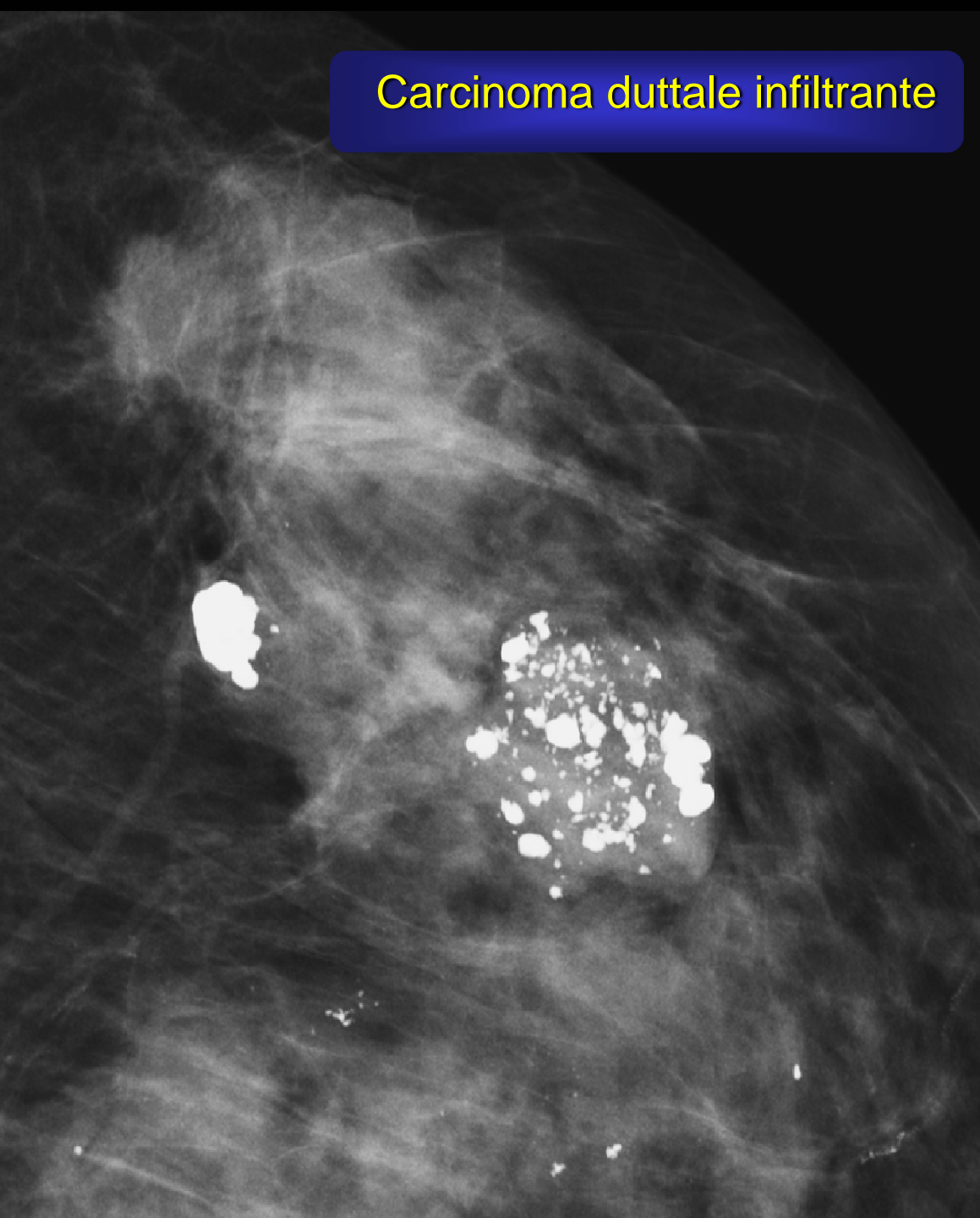
Approfondiamo?

- A) SI
- B) NO

Come?

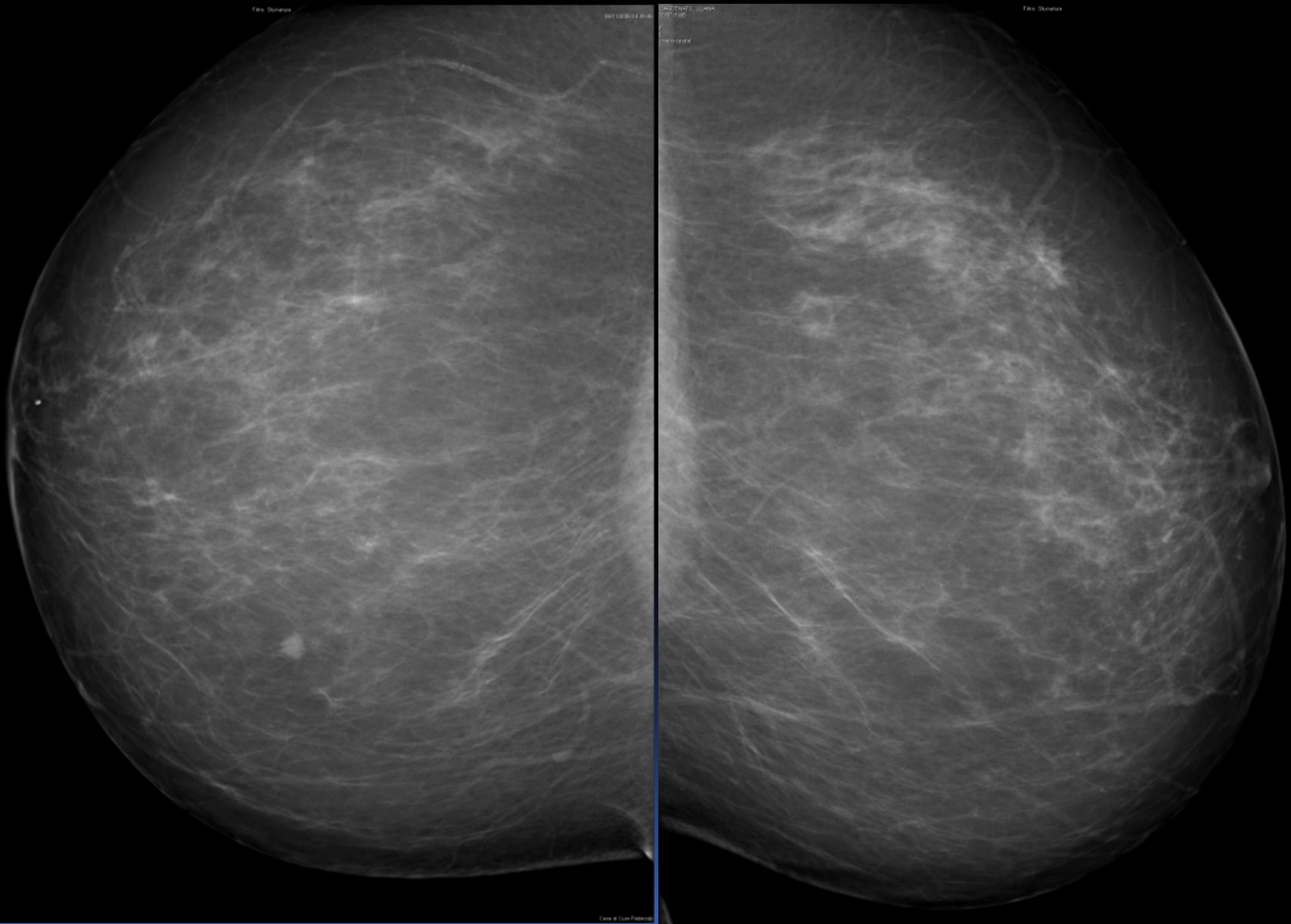
- A) Proiez. supplementare
- B) Compressione mirata
- C) Ingrandimento
- D) Ecografia
- E) C+ D

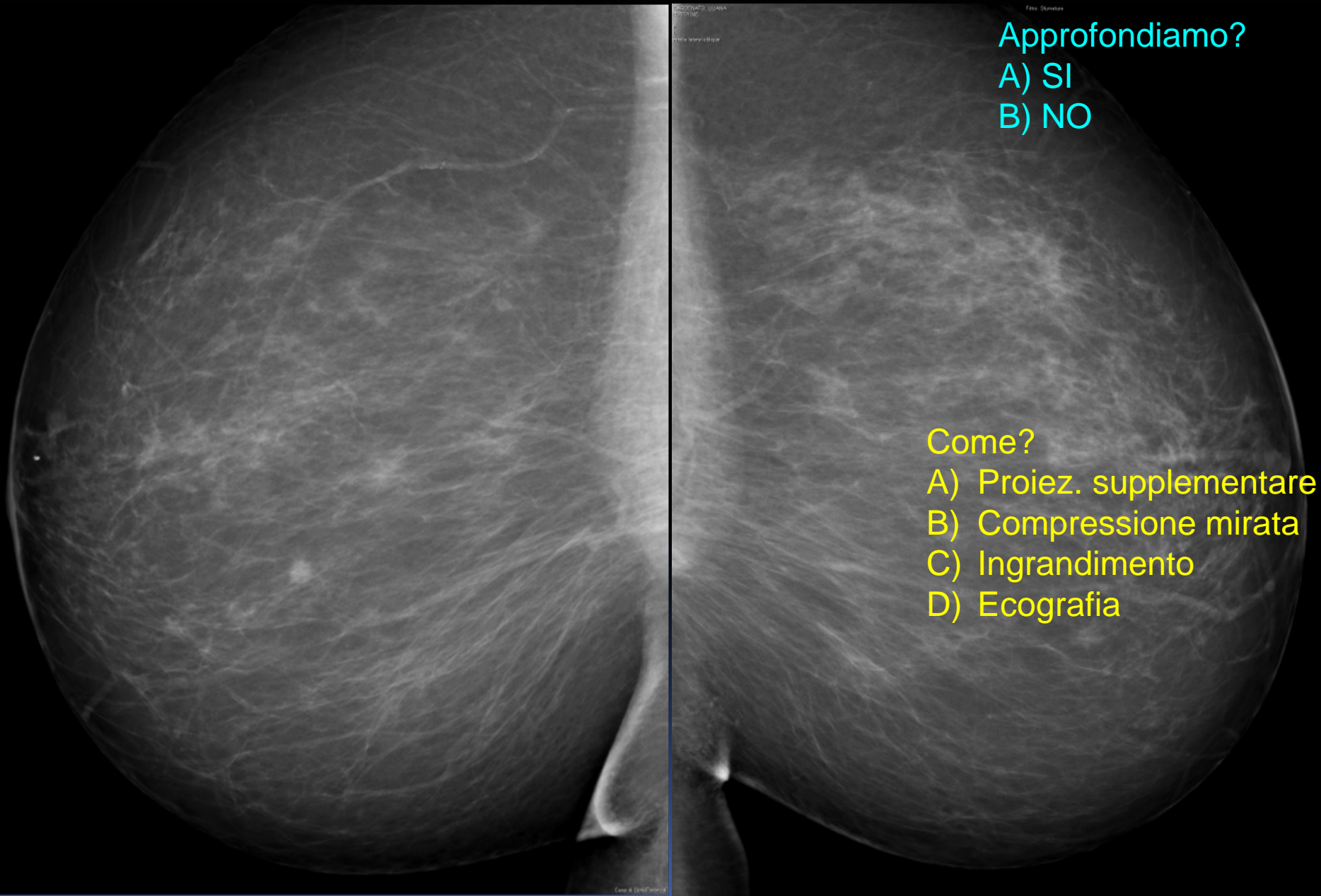
Carcinoma duttale infiltrante



CASO 5

- 57 aa
- asintomatica



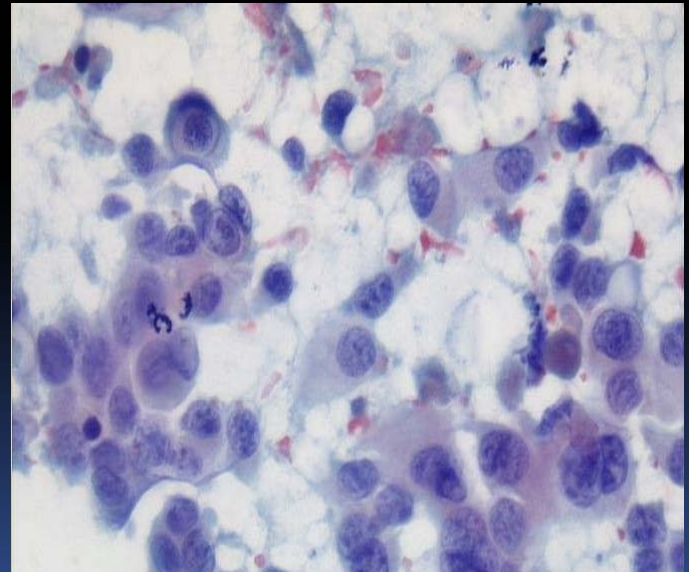
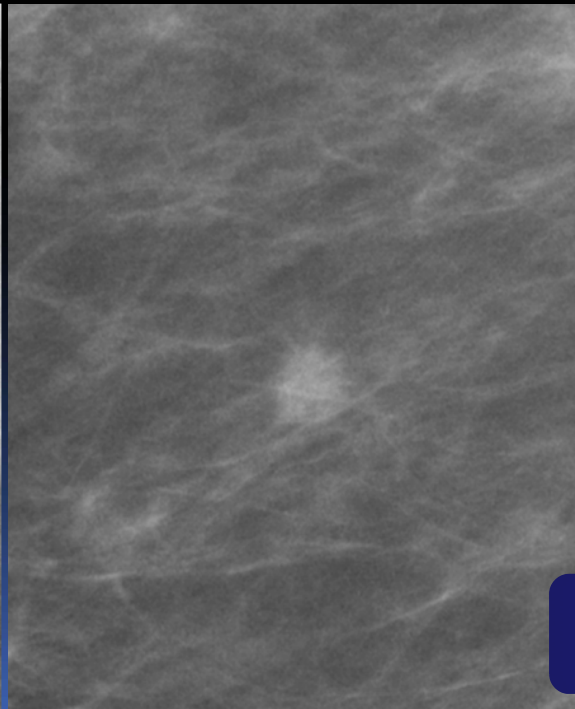
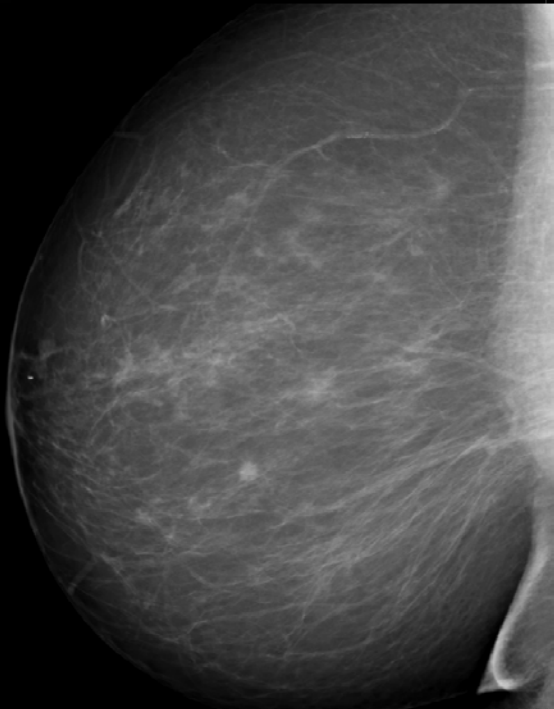
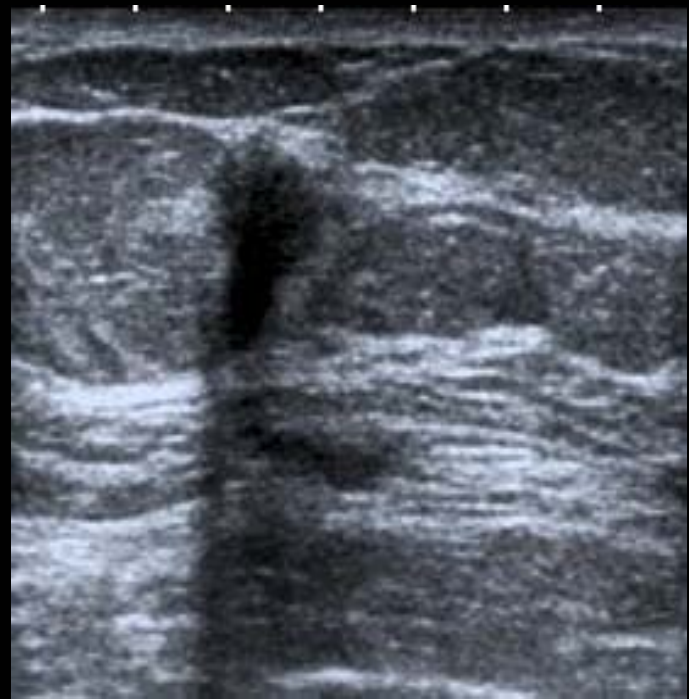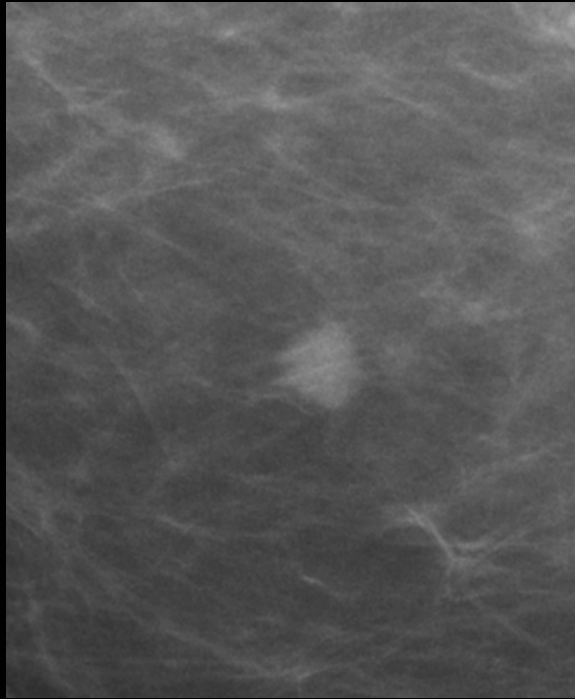
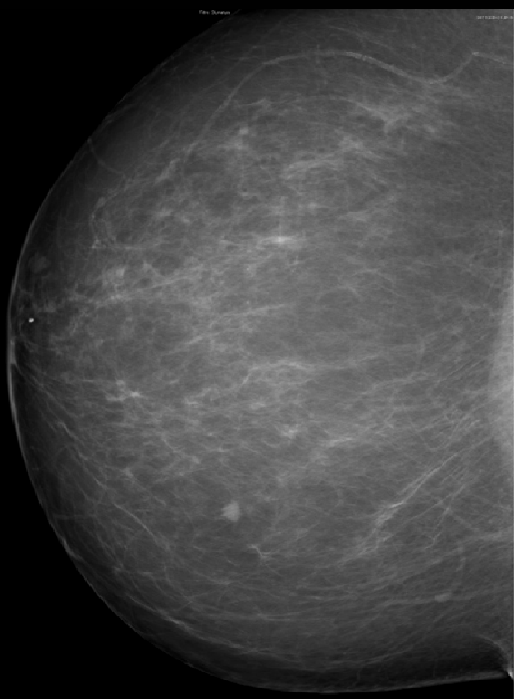


Approfondiamo?

- A) SI
- B) NO

Come?

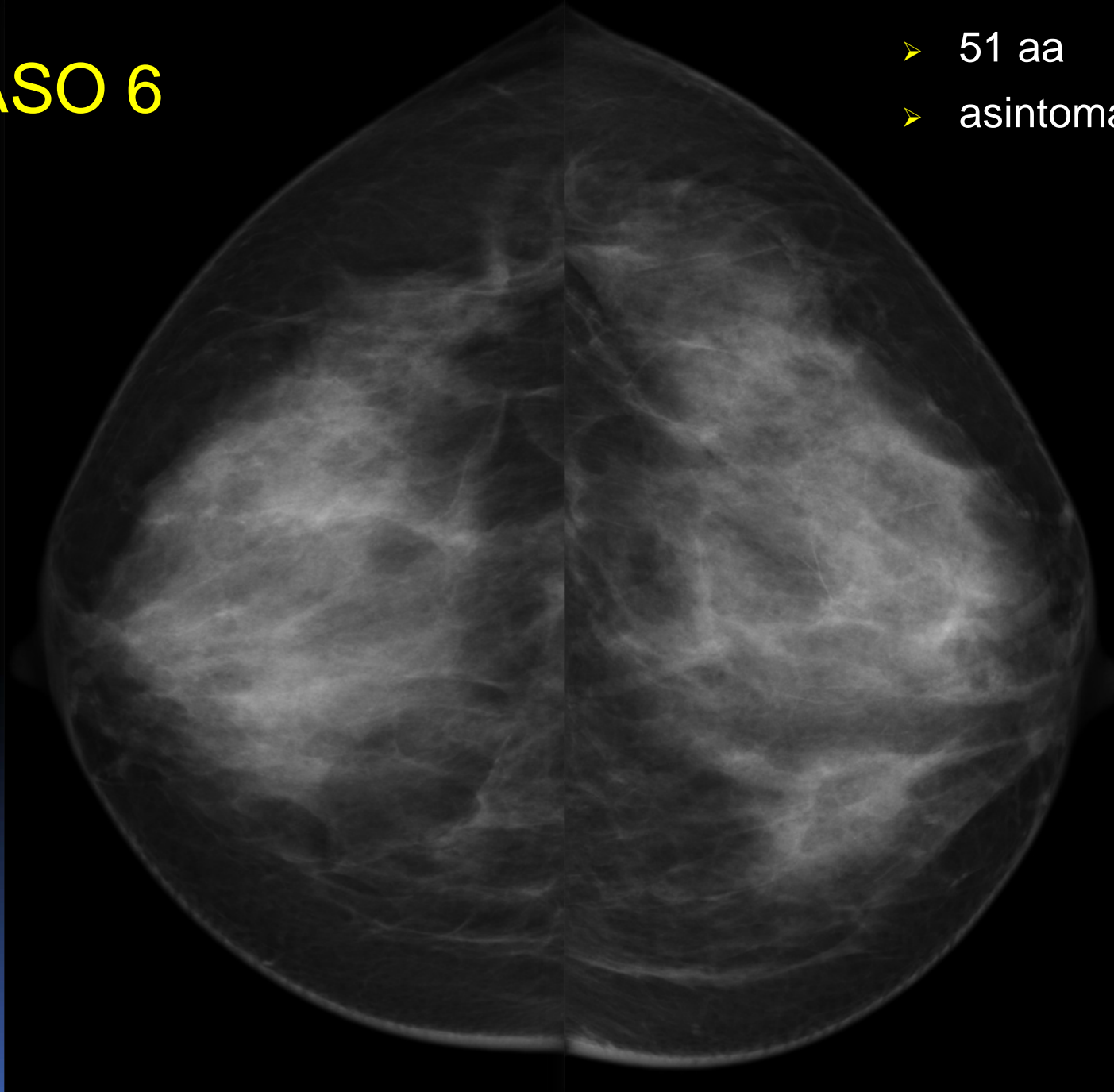
- A) Proiez. supplementare
- B) Compressione mirata
- C) Ingrandimento
- D) Ecografia

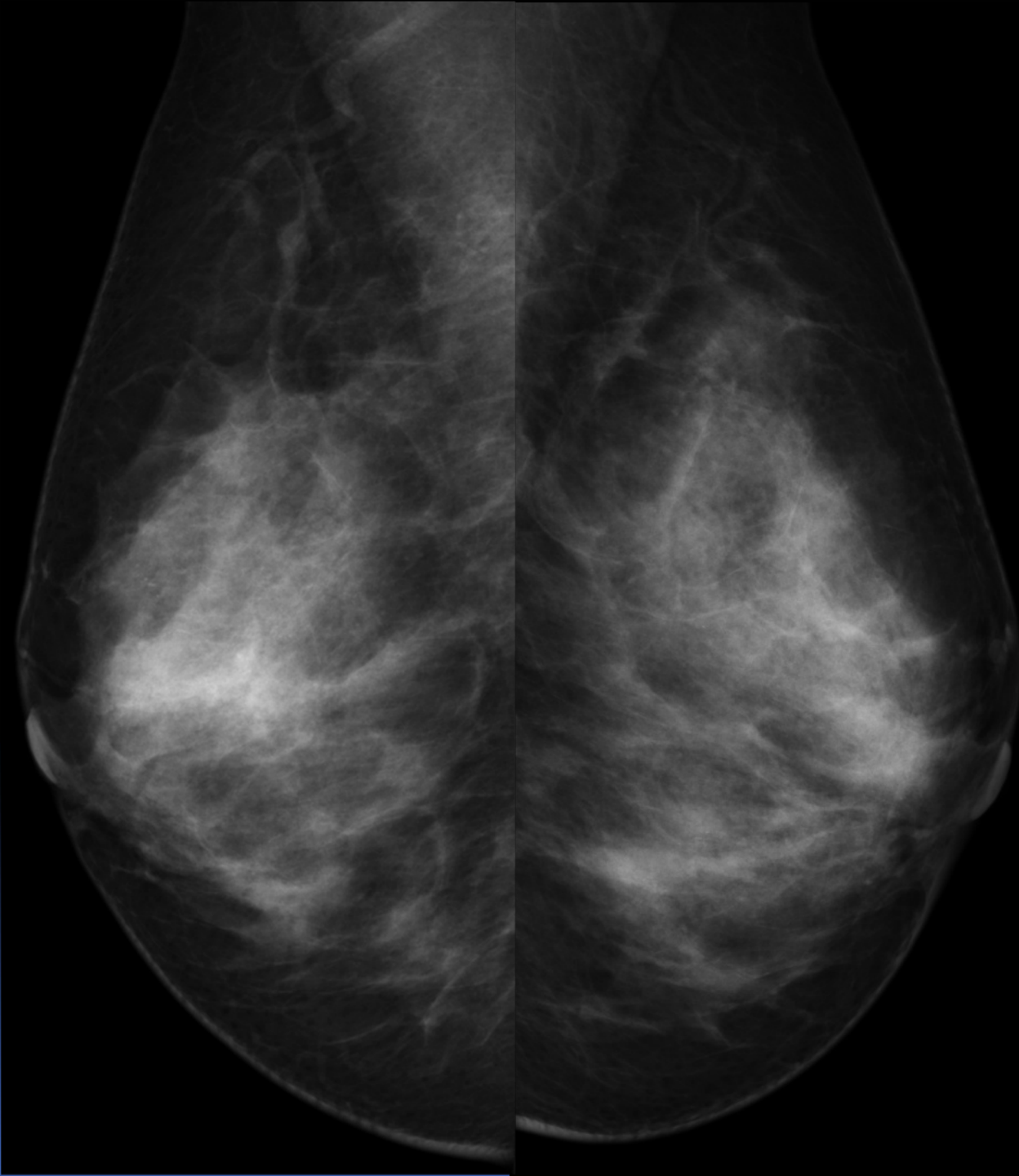


Carcinoma duttale infiltrante

CASO 6

- 51 aa
- asintomatica



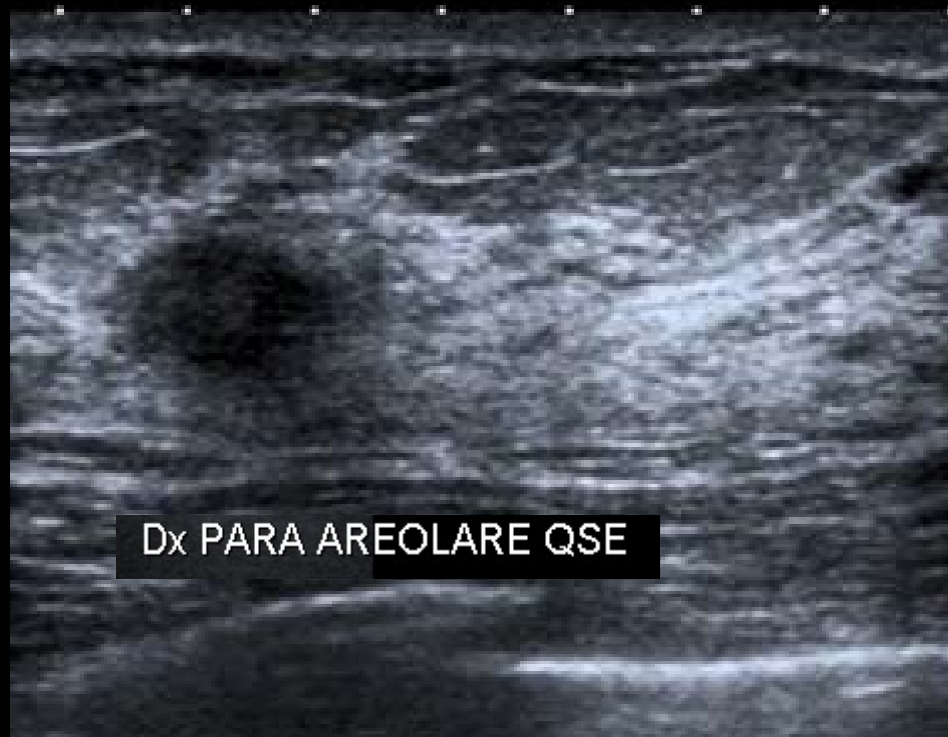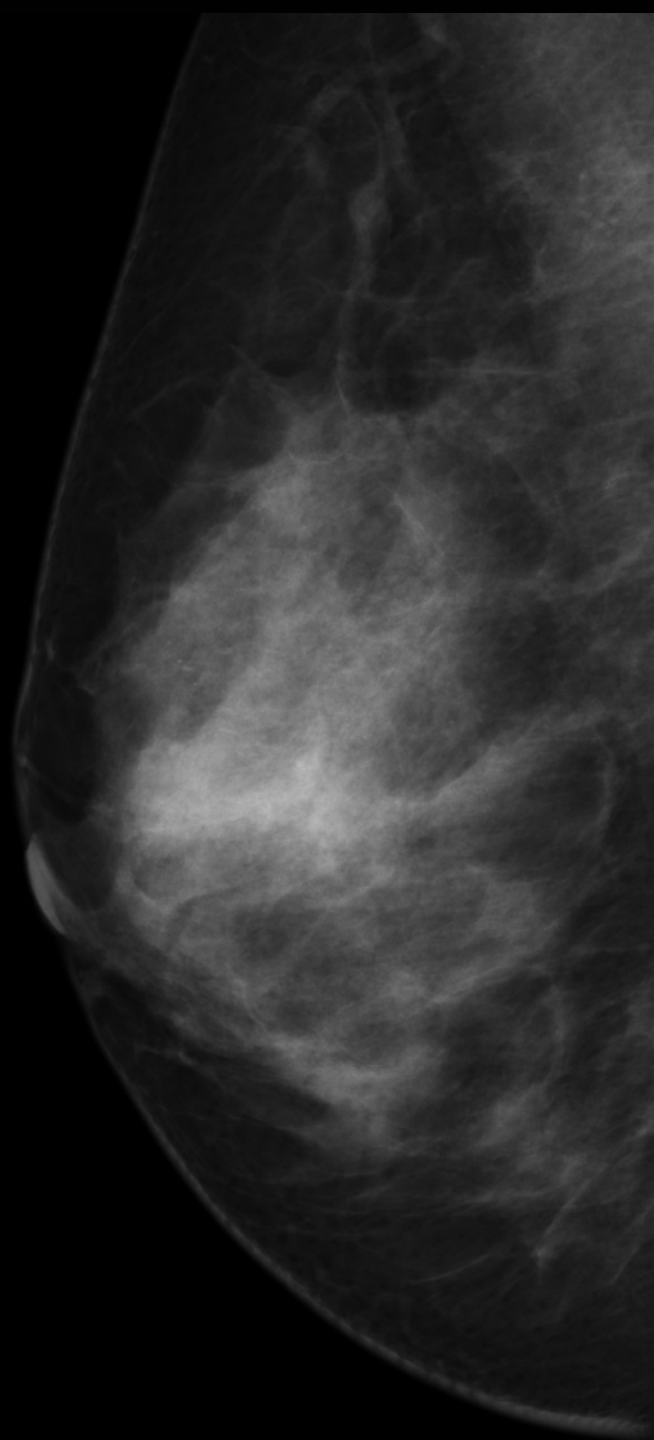


Approfondiamo?

- A) SI
- B) NO

Come?

- A) Proiez. supplementare
- B) Compressione mirata
- C) Ingrandimento
- D) Ecografia

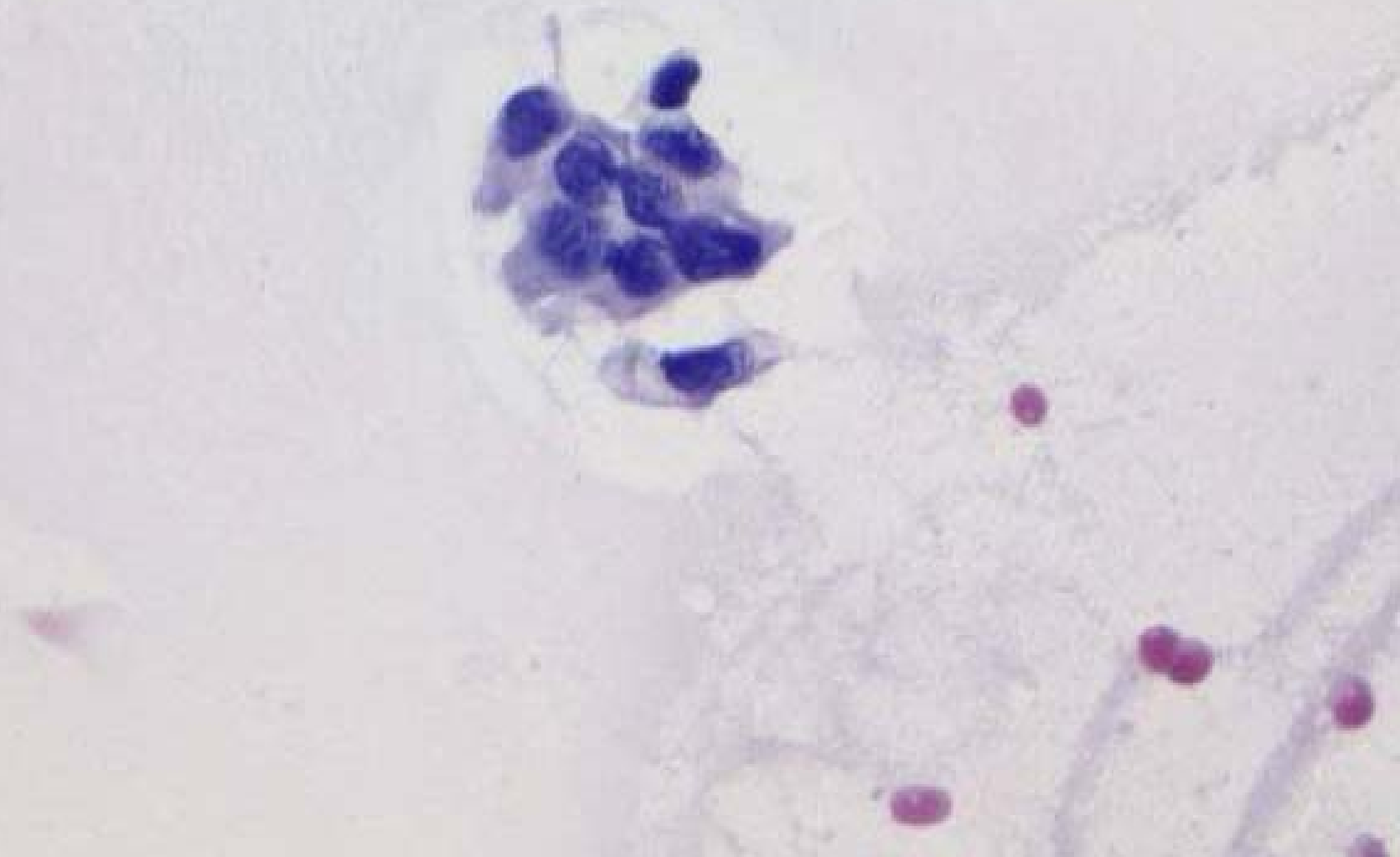


Giudizio ?

A) BI-RADS 3

B) BI-RADS 4

**Aggregati duttulo-lobulari
in assenza di significative atipie
(C2:benigno).**



**Discrepanza
fra il sospetto delle indagini
macroscopiche
e
la benignità del reperto microscopico.**

Cosa fare quindi?

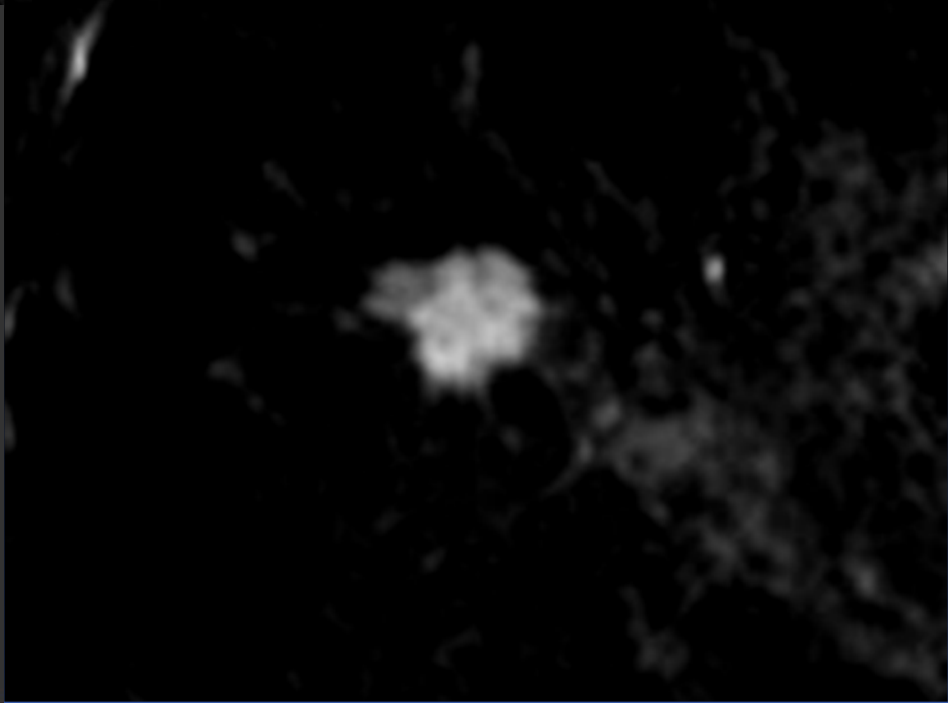
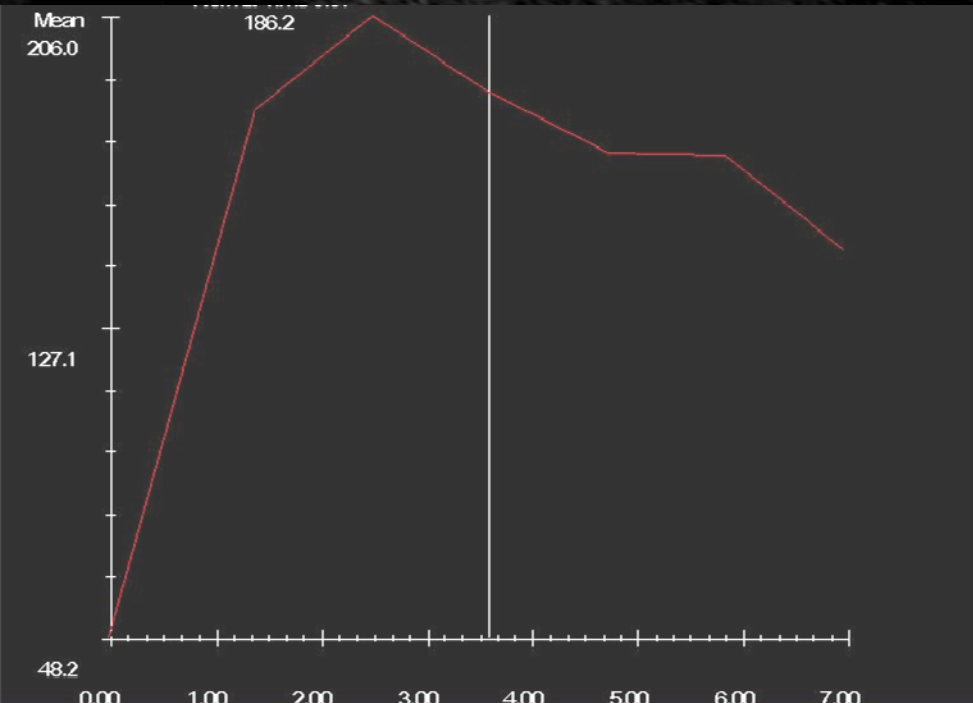
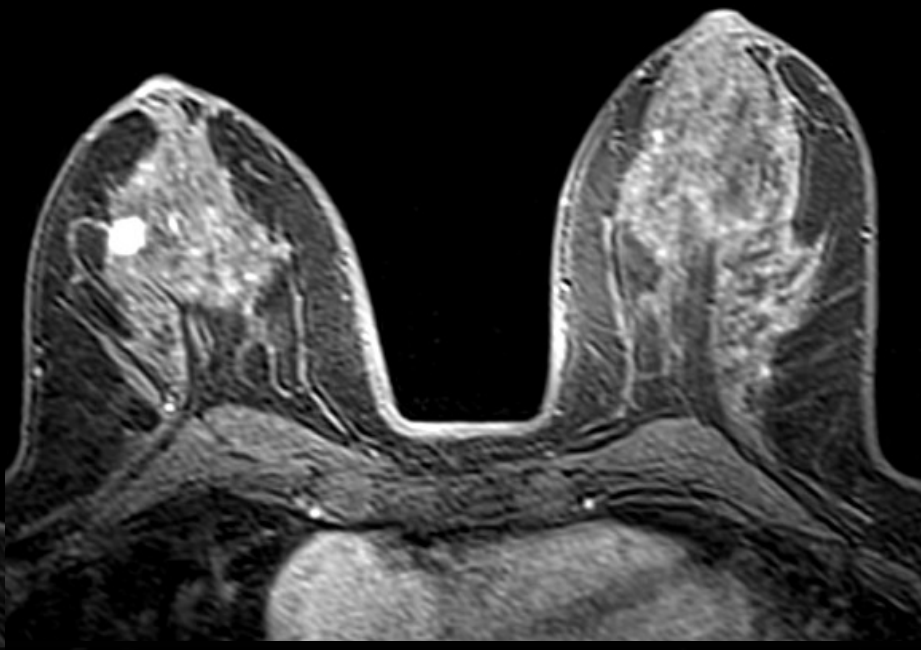
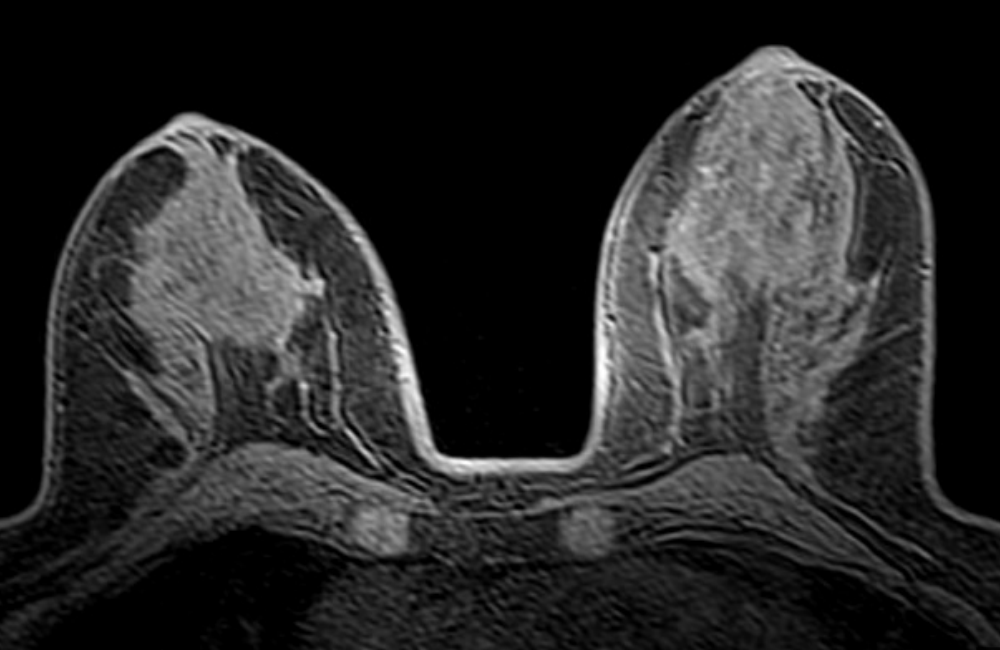
- A. Stop
- B. Prosecuzione dell'iter
- C. Follow up a 6 mesi

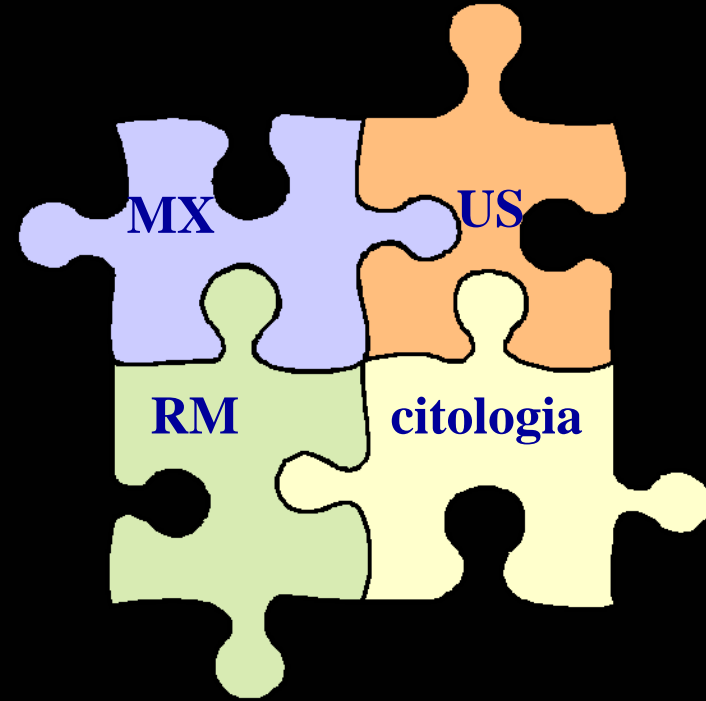
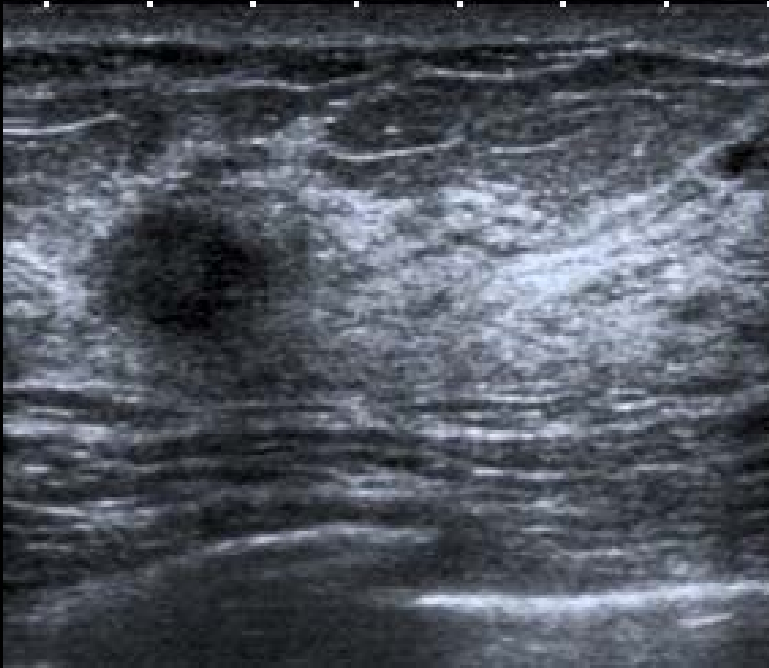**Discrepanza
fra il sospetto delle indagini
macroscopiche
e
la benignità del reperto microscopico.**

Necessario proseguimento delle indagini!

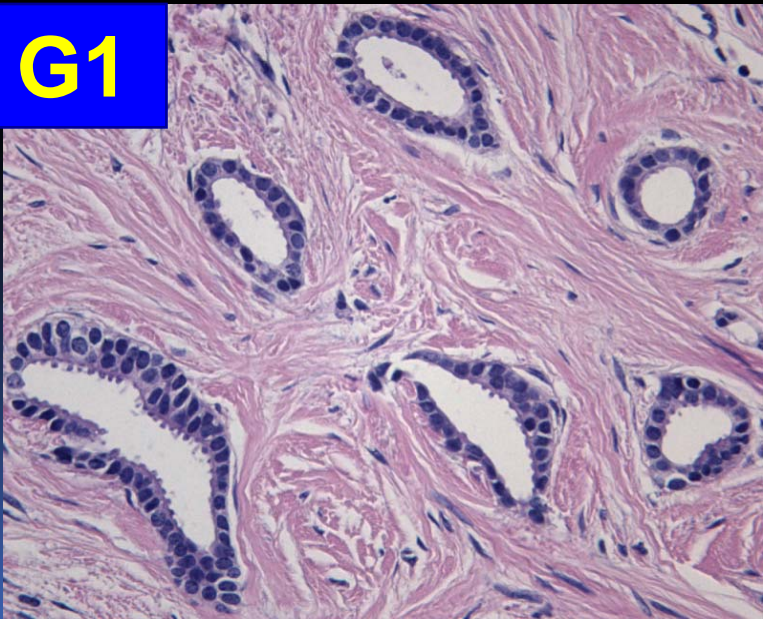
Quale indagine?

-  A. CORE BIOPSY
- B. RM



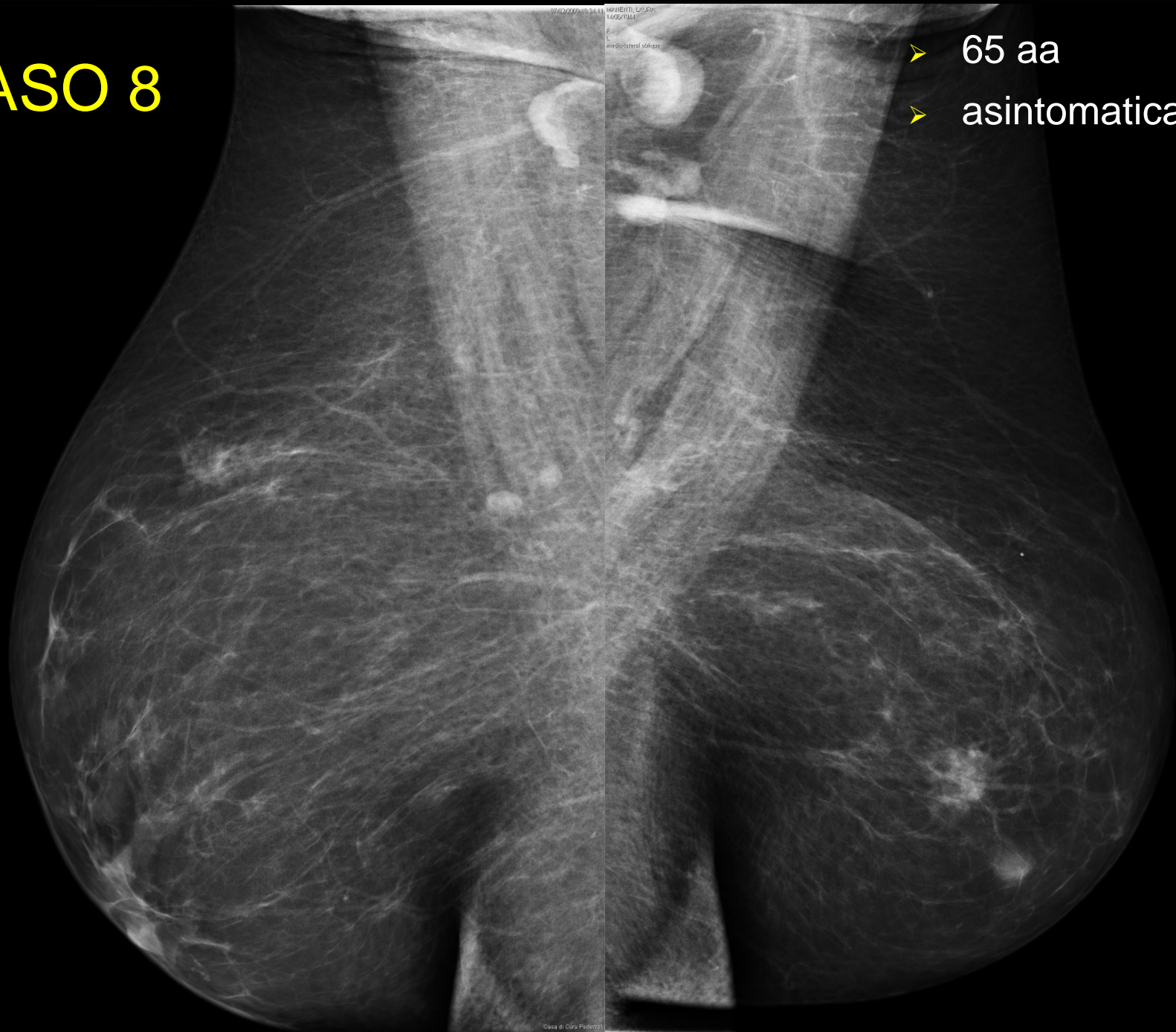


G1

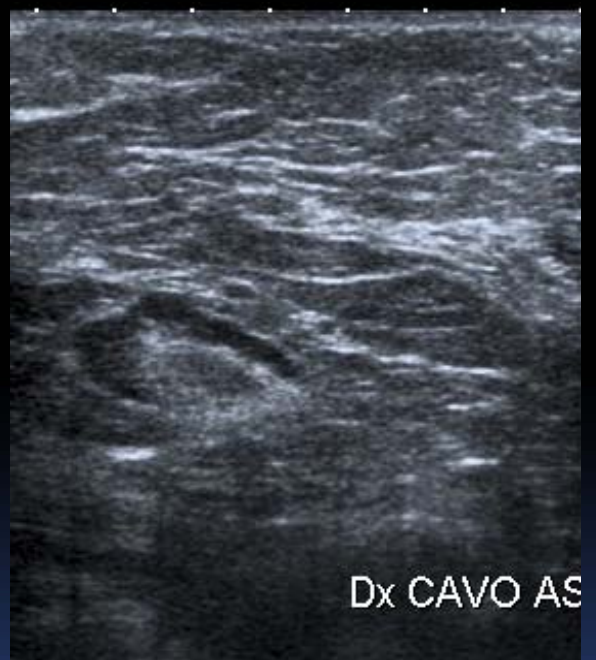
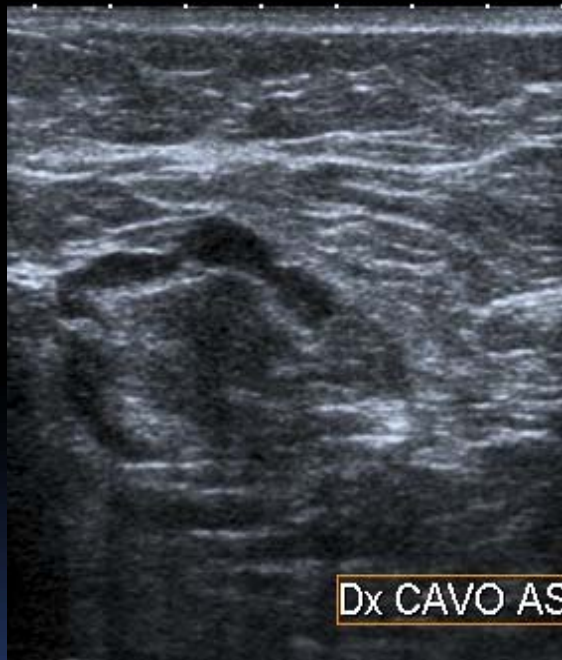
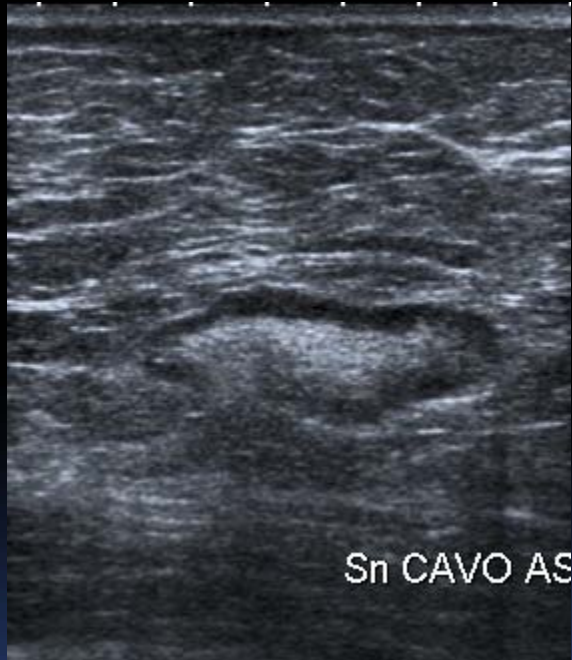Carcinoma tubulare infiltrante

CASO 8



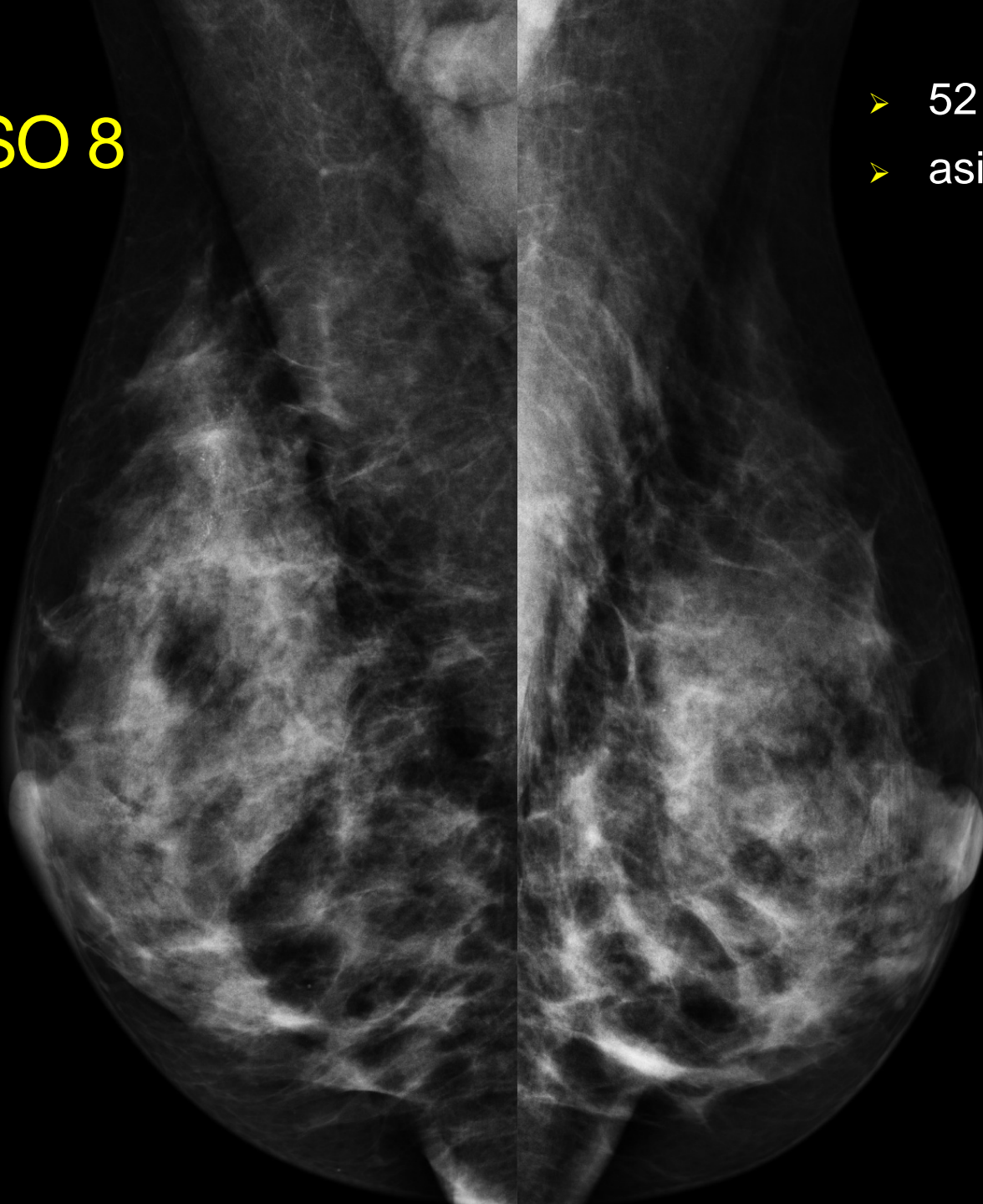
- 65 aa
- asintomatica

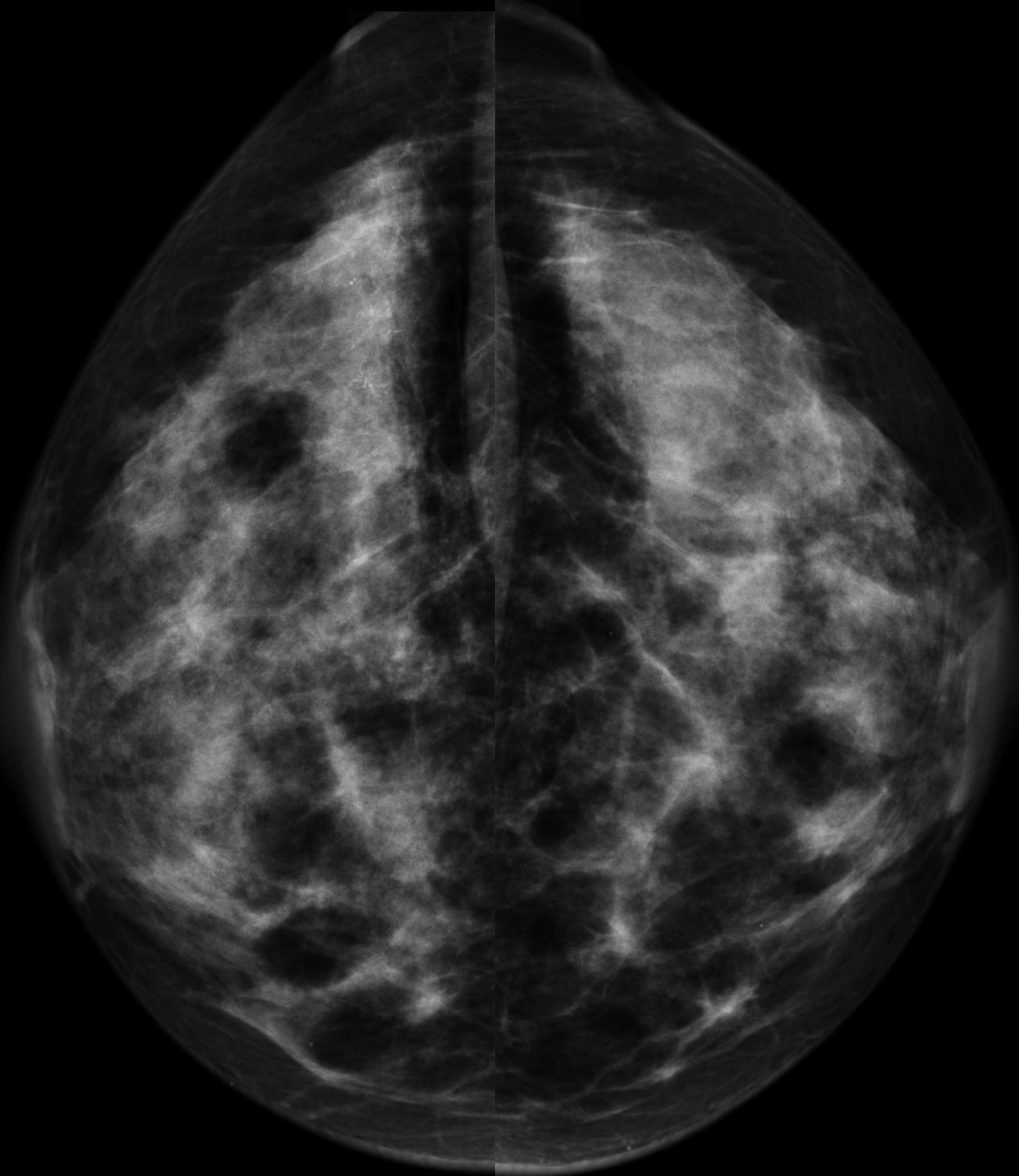


Artrite reumatoide

CASO 8

- 52 aa
- asintomatica





Approfondiamo?

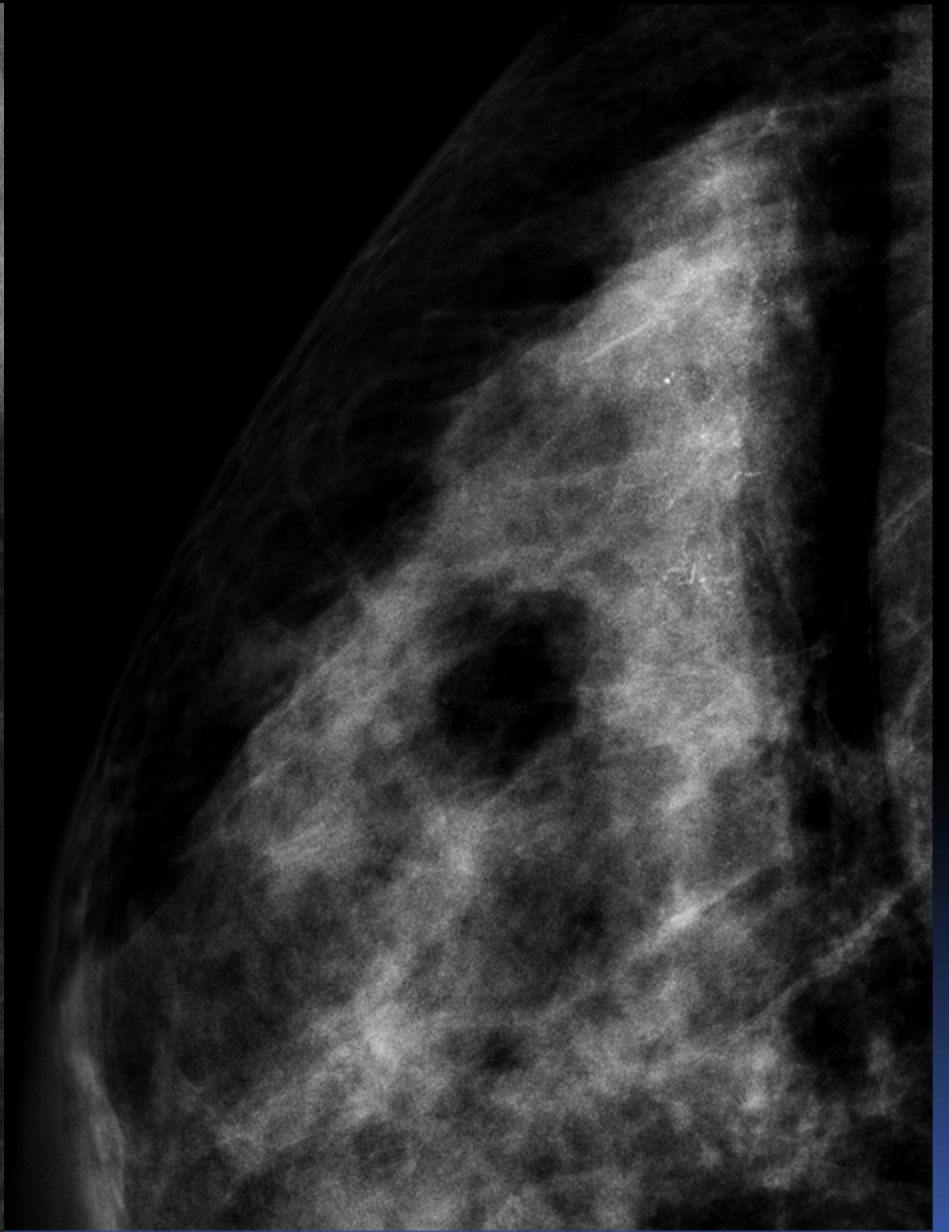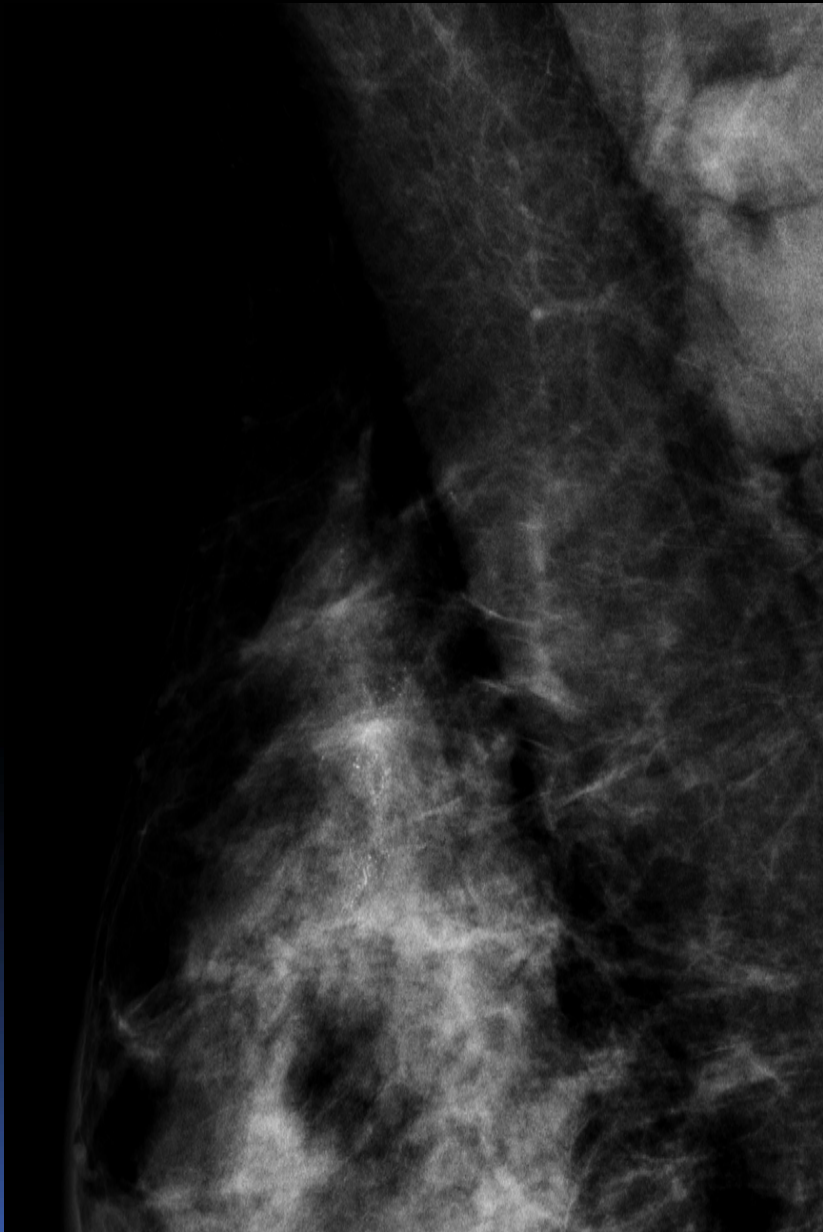
- A) si
- B) no

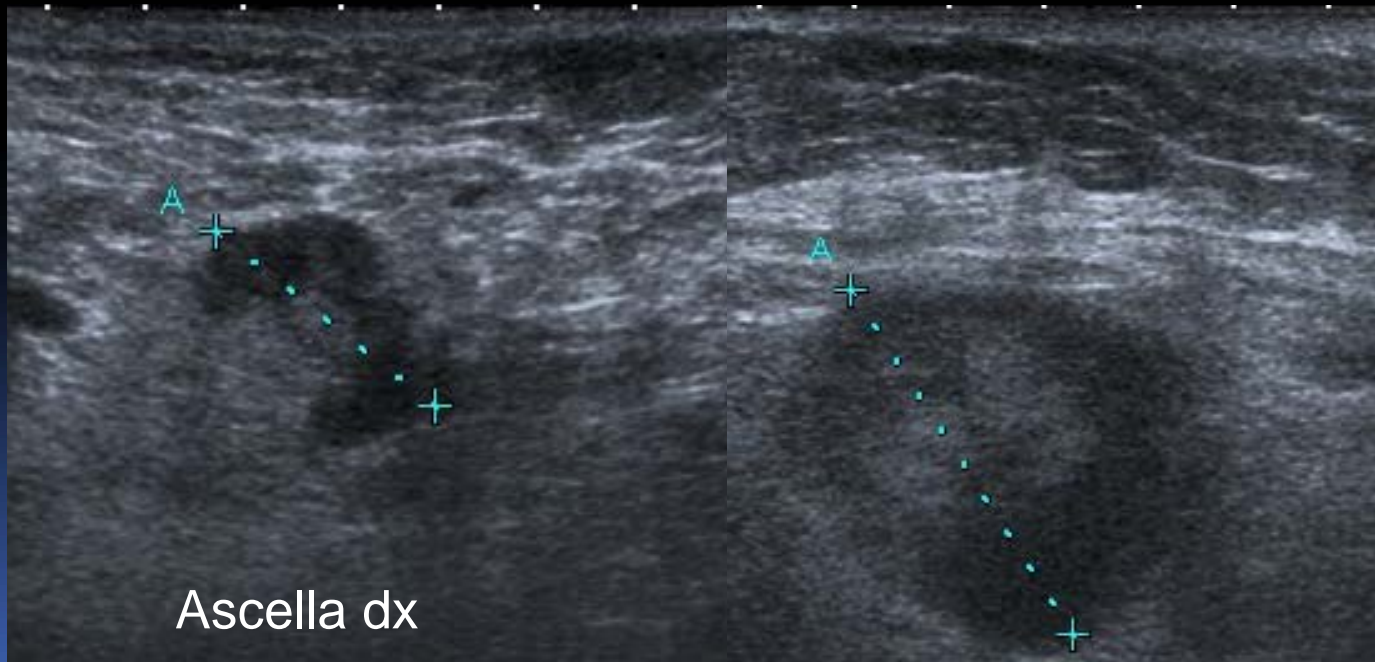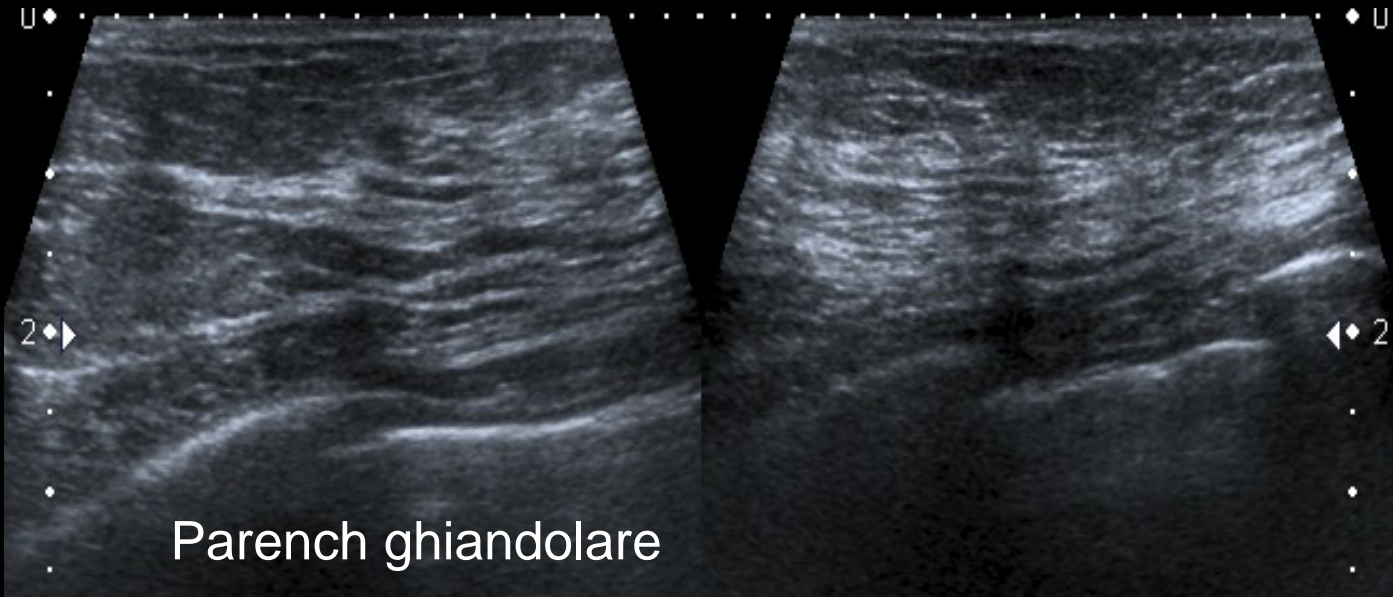
Dove?

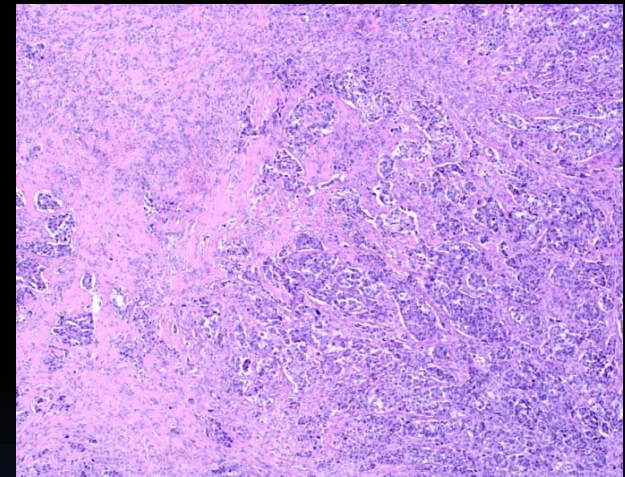
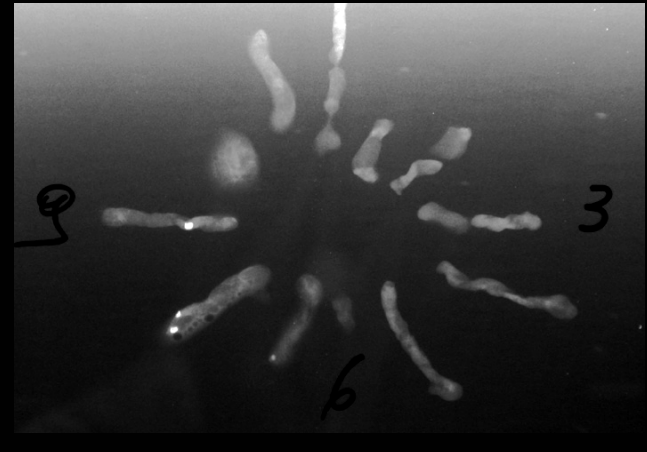
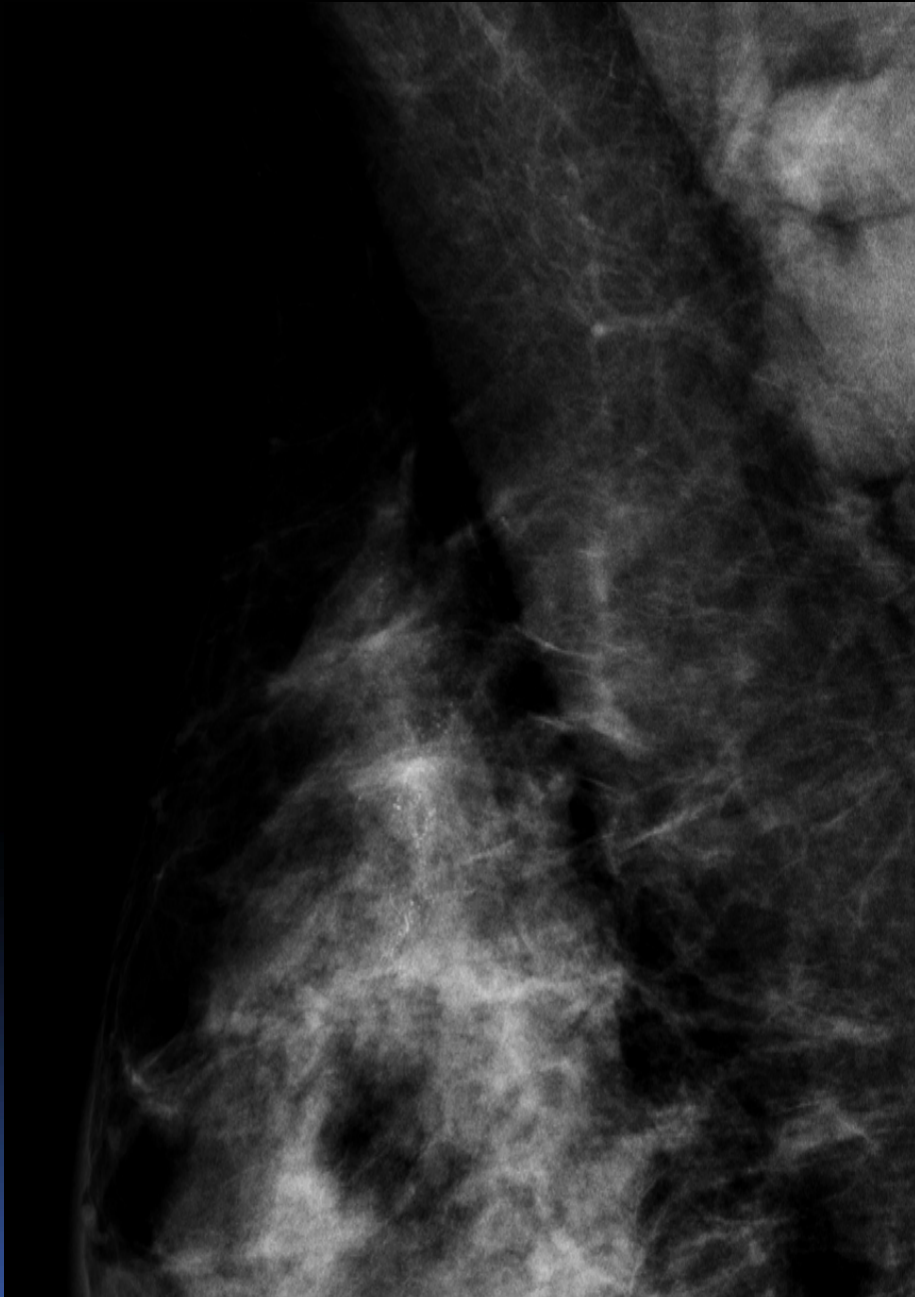
- A) Parench ghiandol
- B) Cavo ascellare
- C) Entrambi

Come?

- A) Proiez. supplementare
- B) Compressione mirata
- C) Ingrandimento
- D) Ecografia
- E) C+D

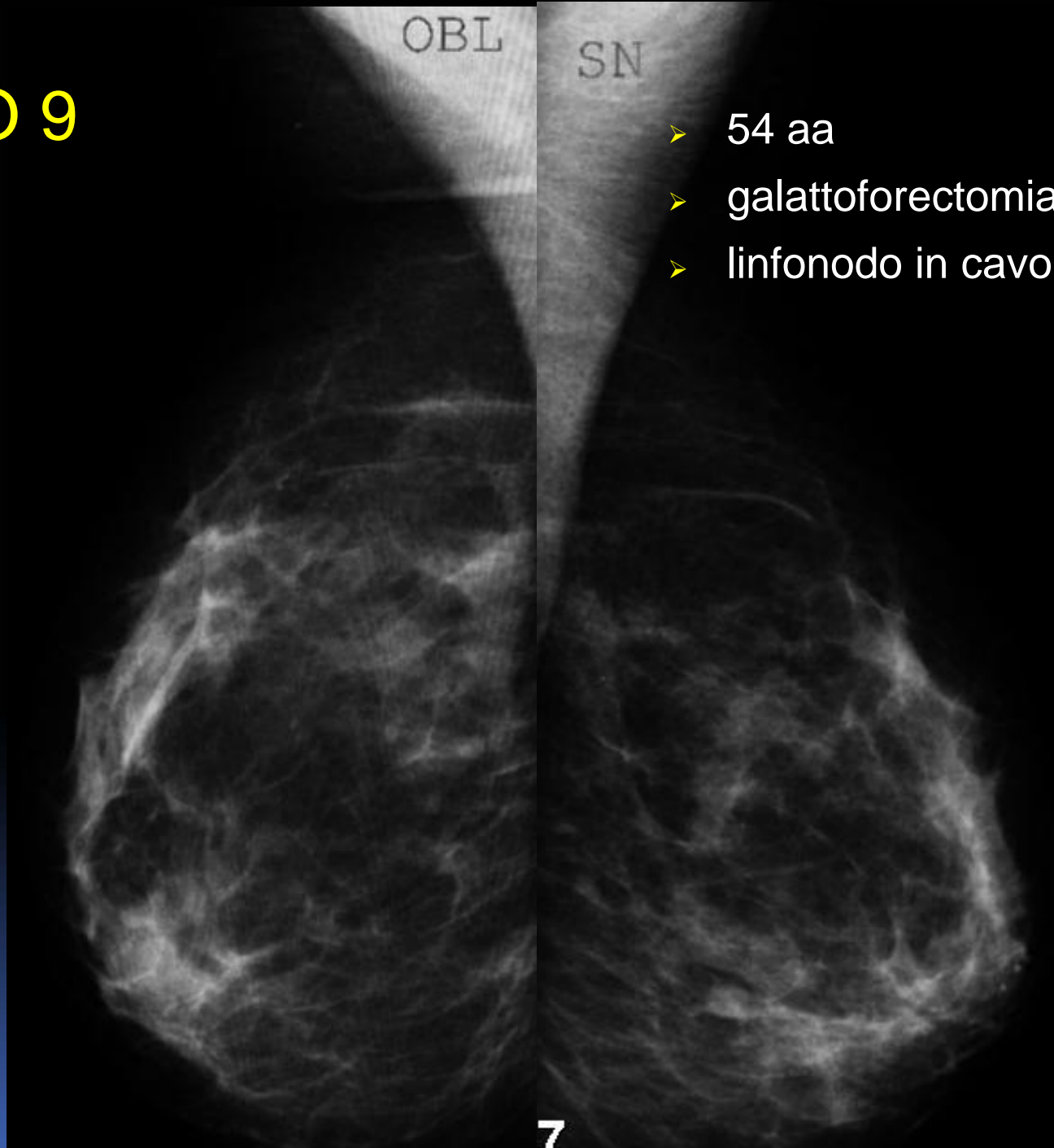




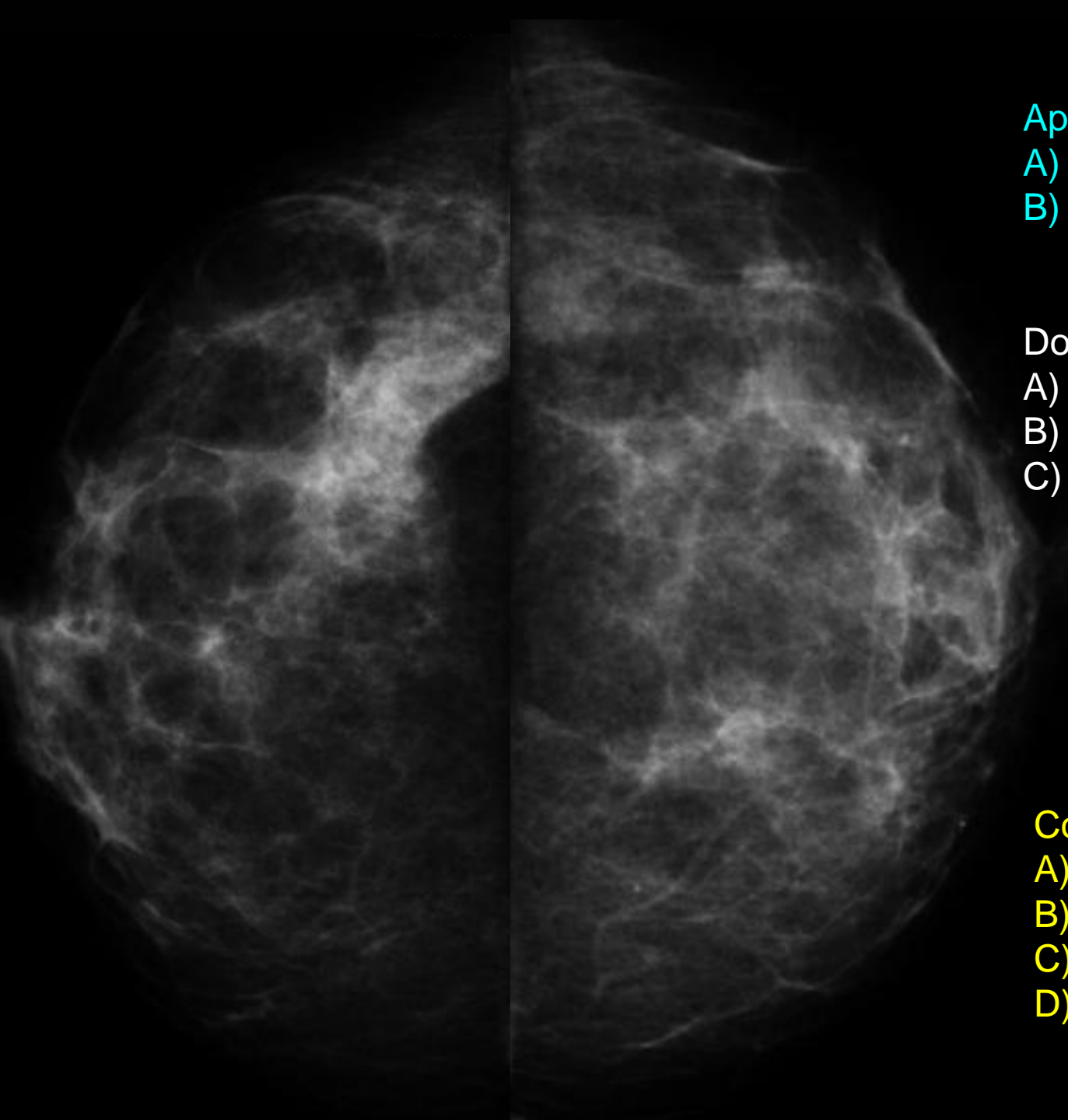


K duttale con
coinvolgimento dei
linfonodi ascellari

CASO 9



- 54 aa
- galattoforectomia dx
- linfonodo in cavo ascellare sn



Approfondiamo?

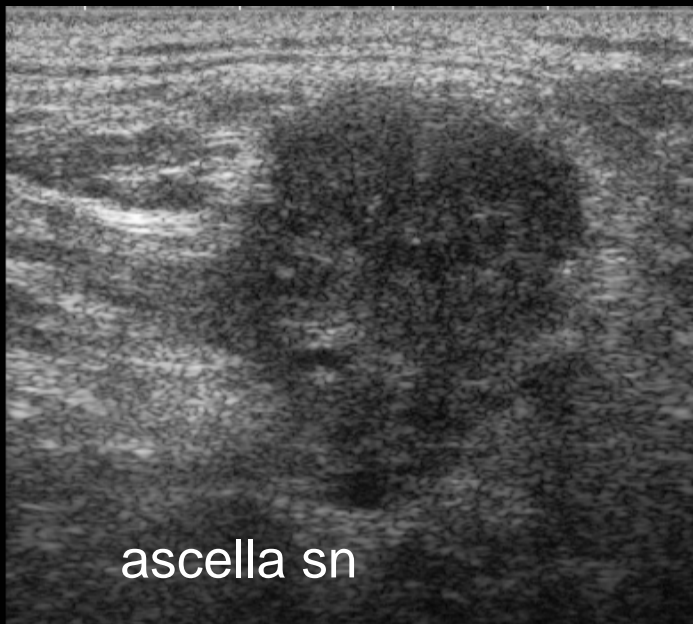
- A) si
- B) no

Dove?

- A) Parench ghiandol
- B) Cavo ascellare
- C) entrambi

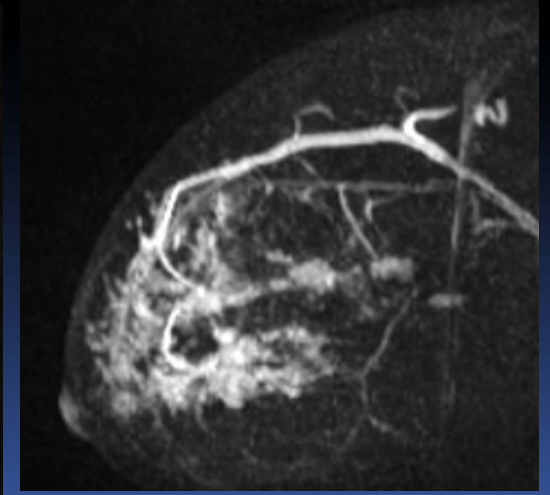
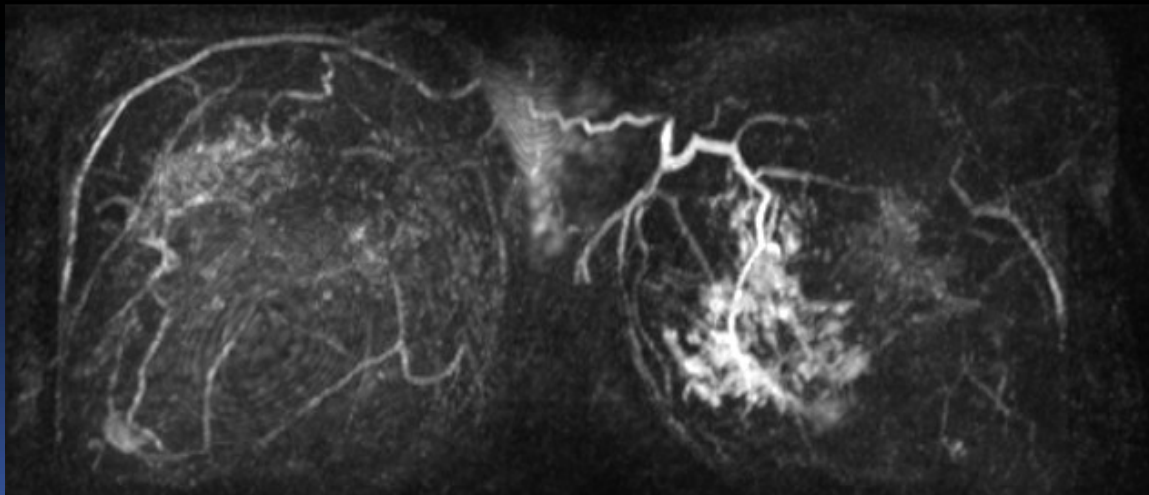
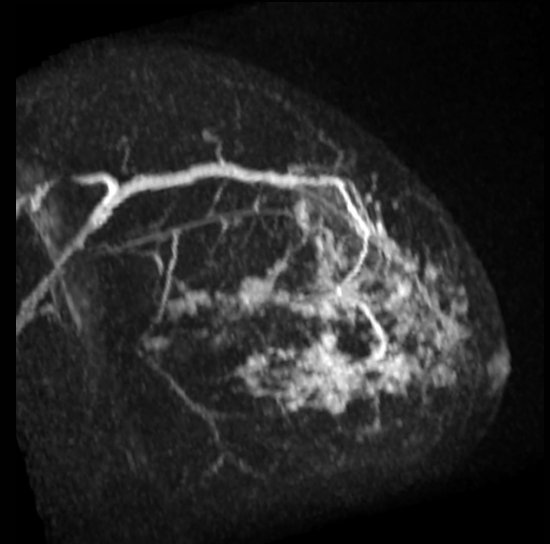
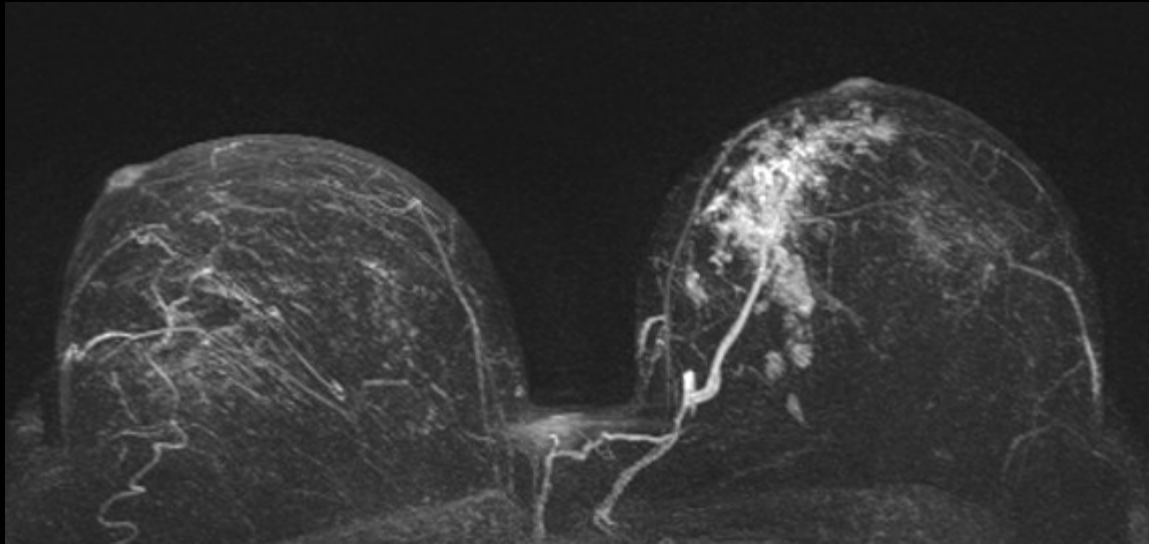
Come?

- A) Proiez. supplementare
- B) Compressione mirata
- C) Ingrandimento
- D) Ecografia

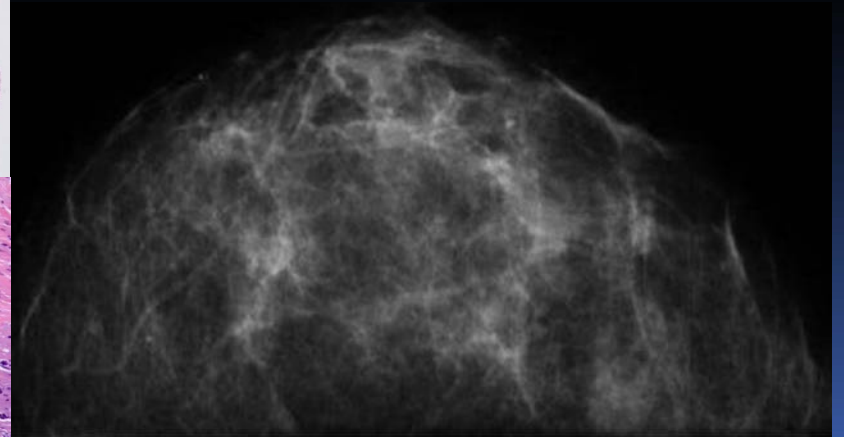
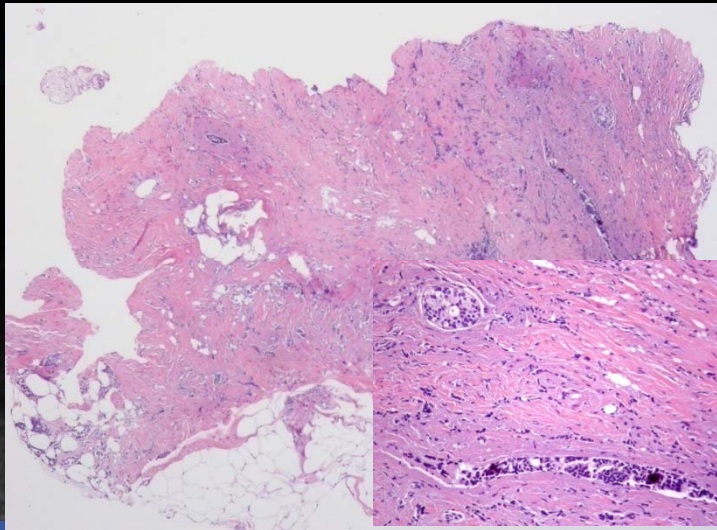
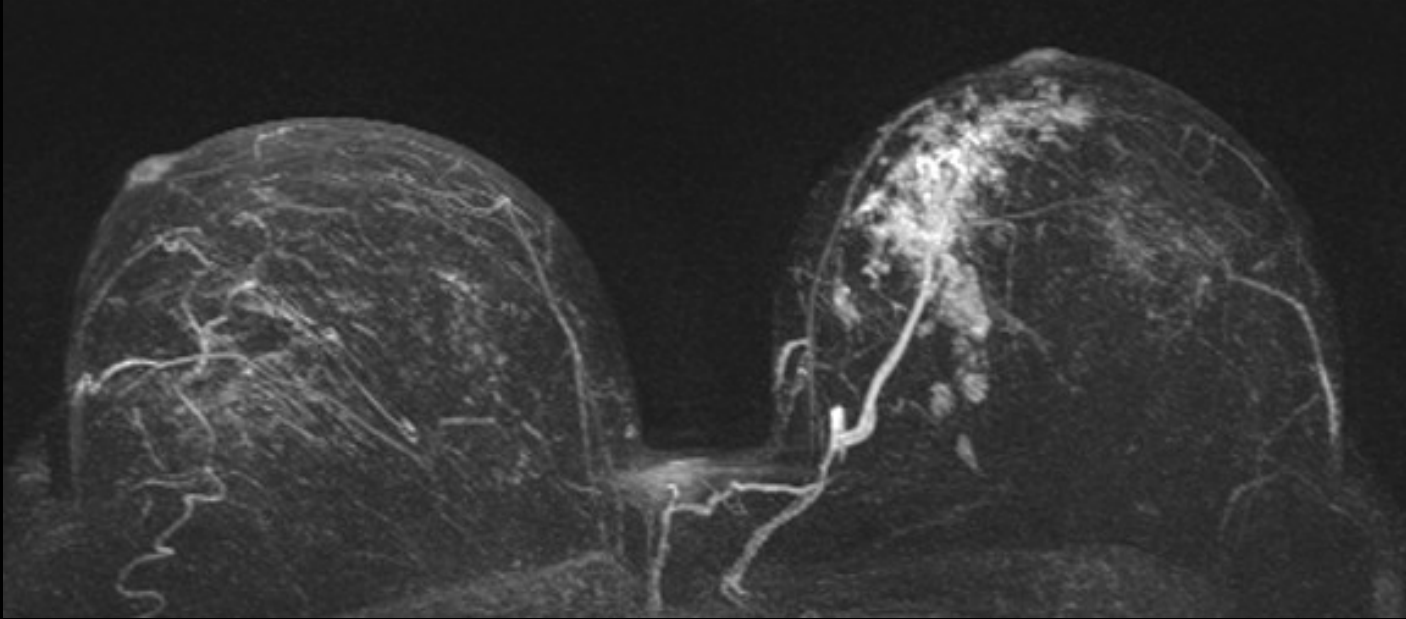


C5
sospetto
per metastasi
di origine mammaria

Iter successivo: RM !

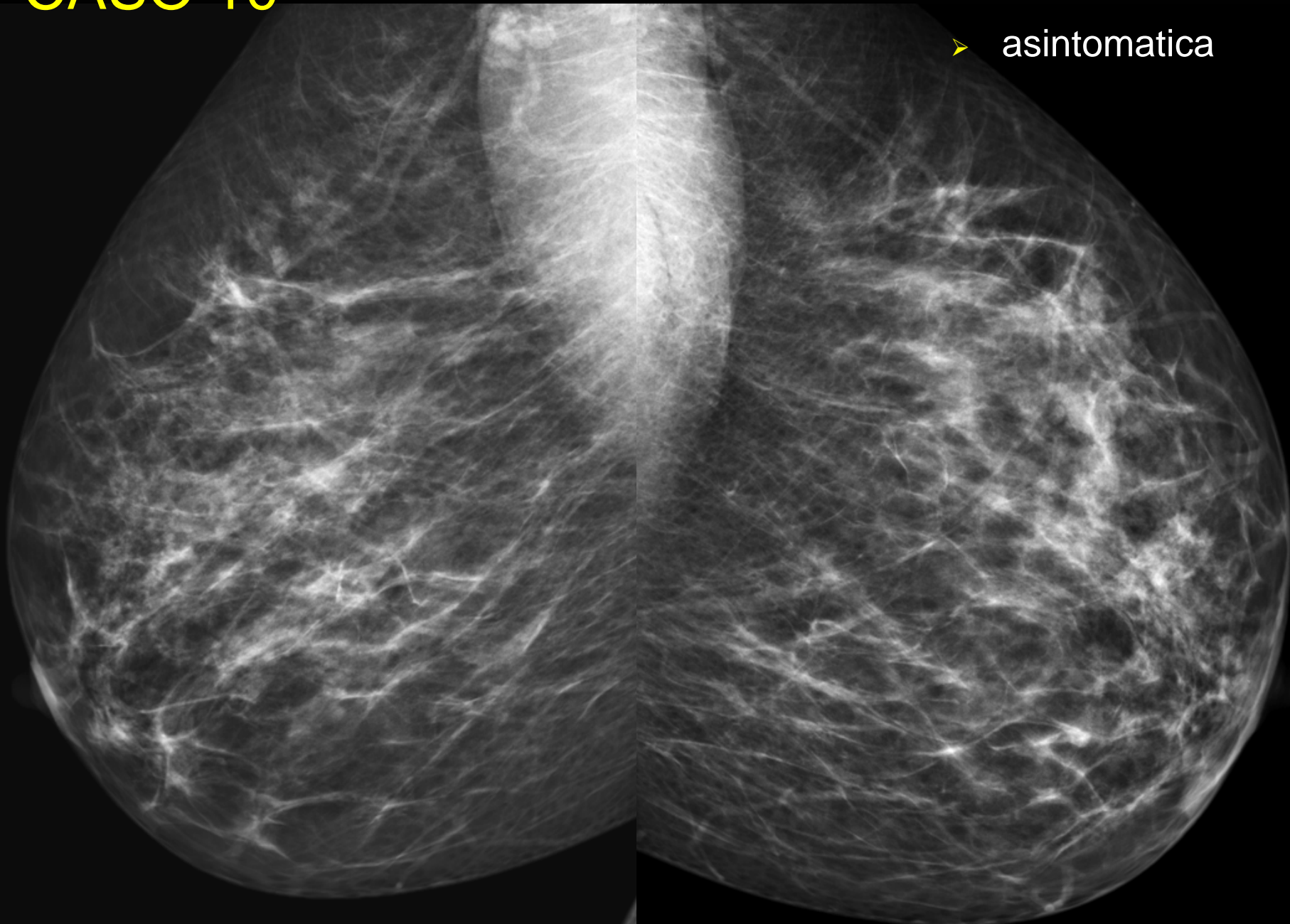


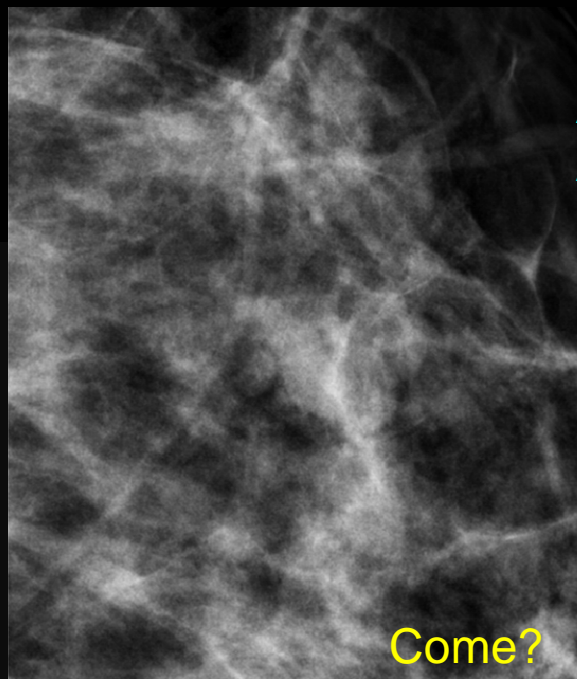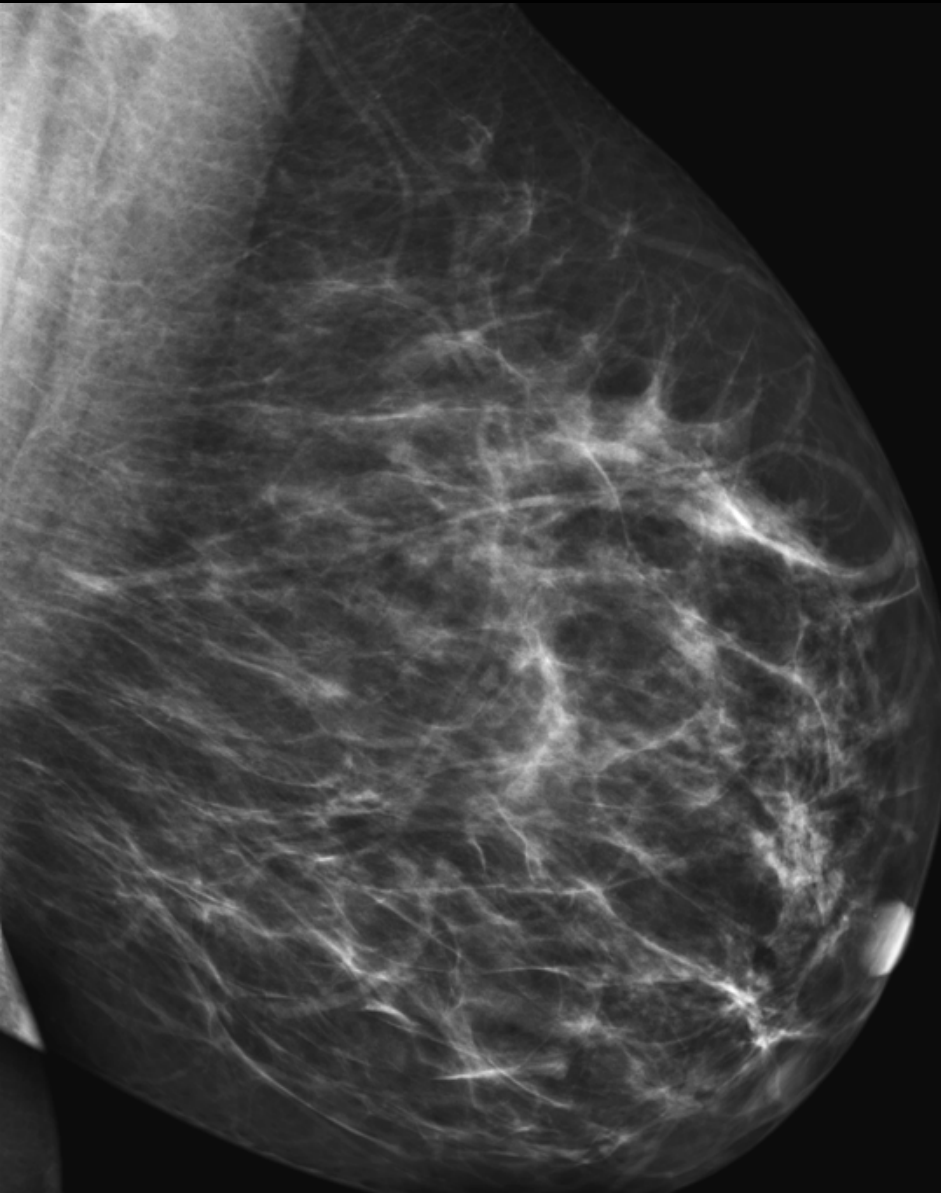
carcinoma lobulare
T4 – N1 – M0



CASO 10

- 63 aa
- asintomatica



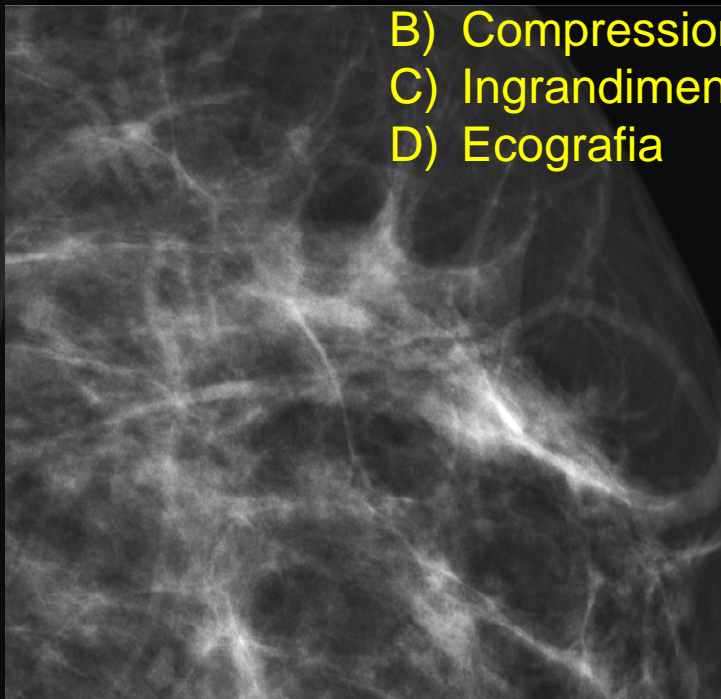


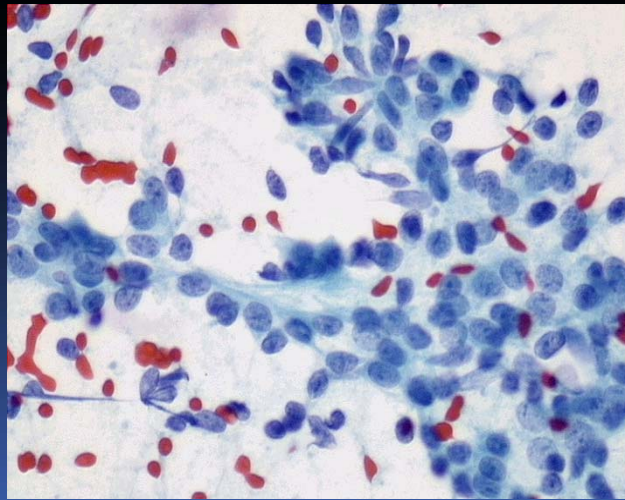
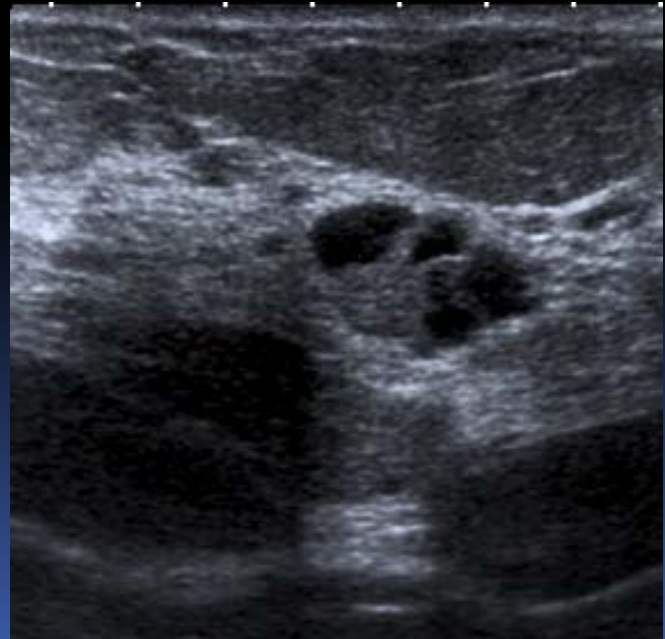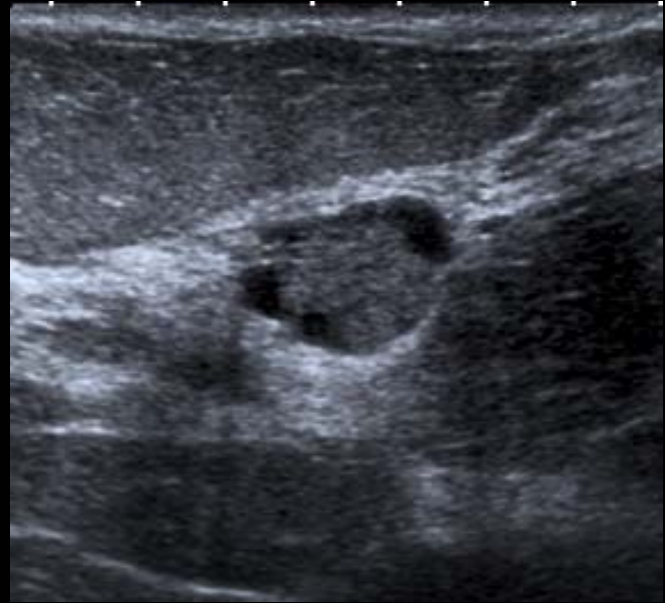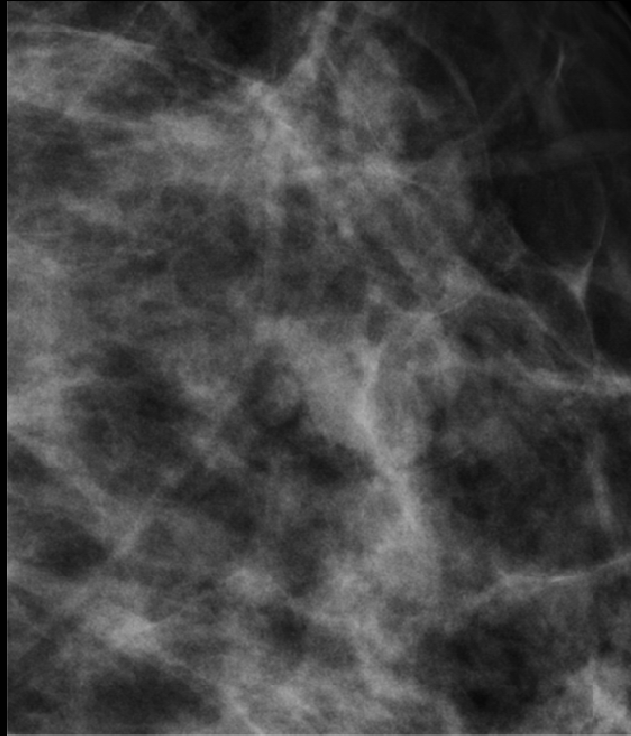Approfondiamo?

- A) si
- B) no

Come?

- A) Proiez. supplementare
- B) Compressione mirata
- C) Ingrandimento
- D) Ecografia





Mastopatia
fibrocistica

CASO 11

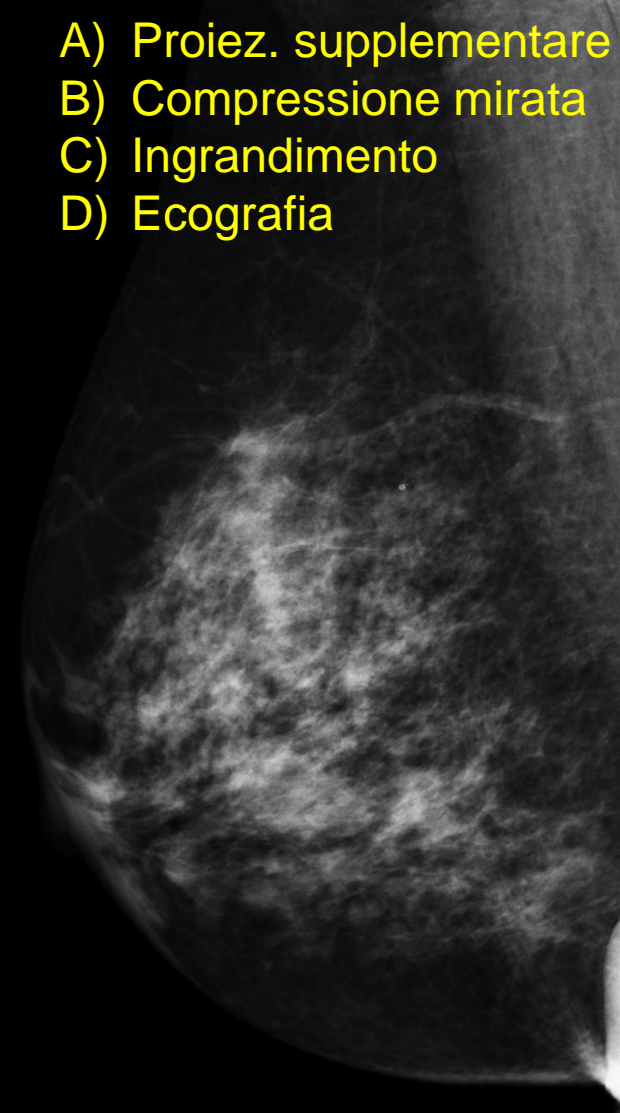
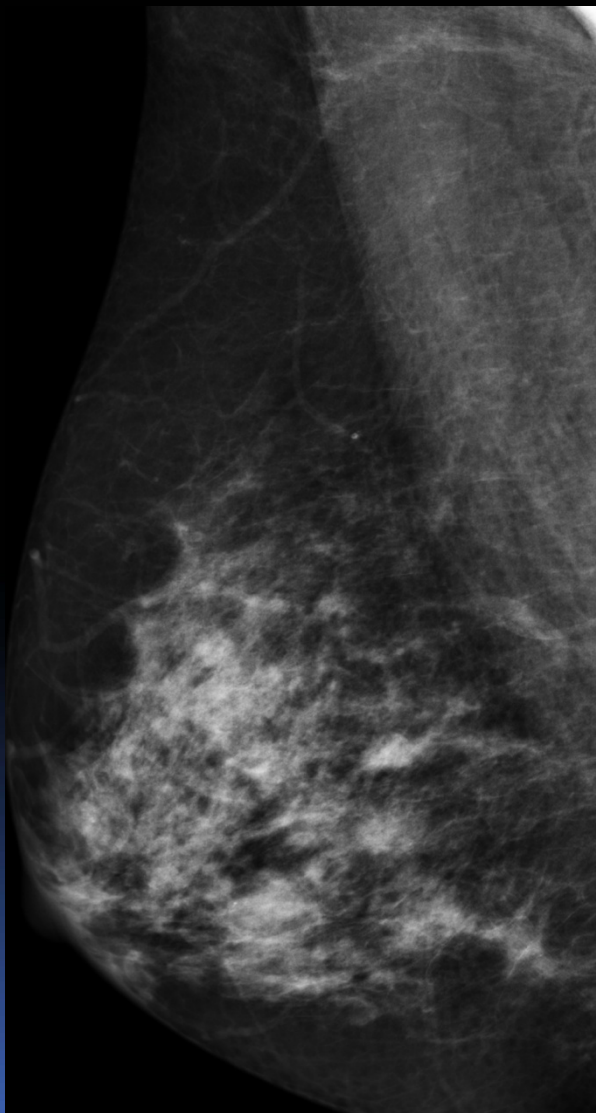
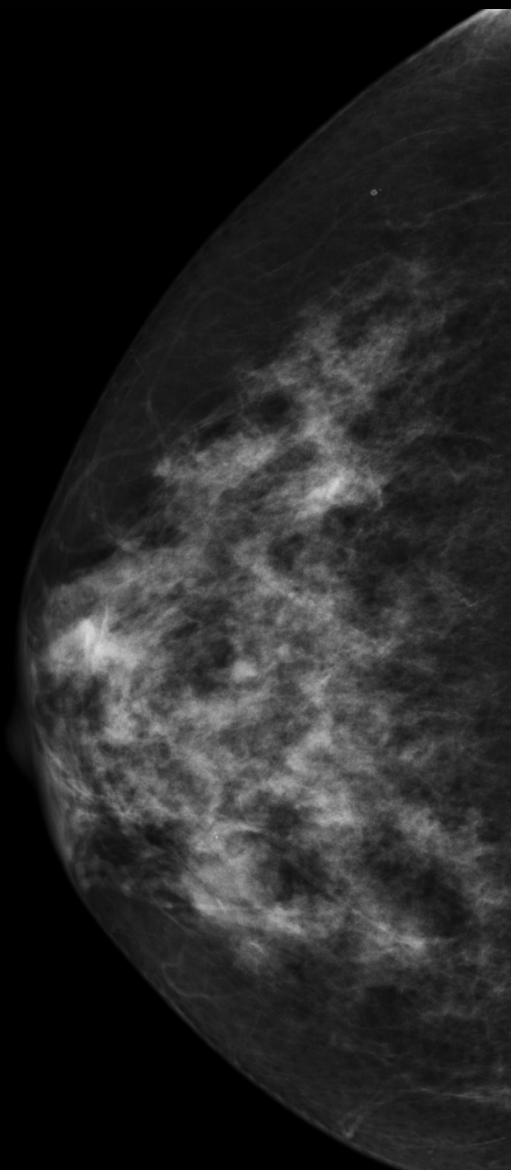
- 51 aa
- asintomatica

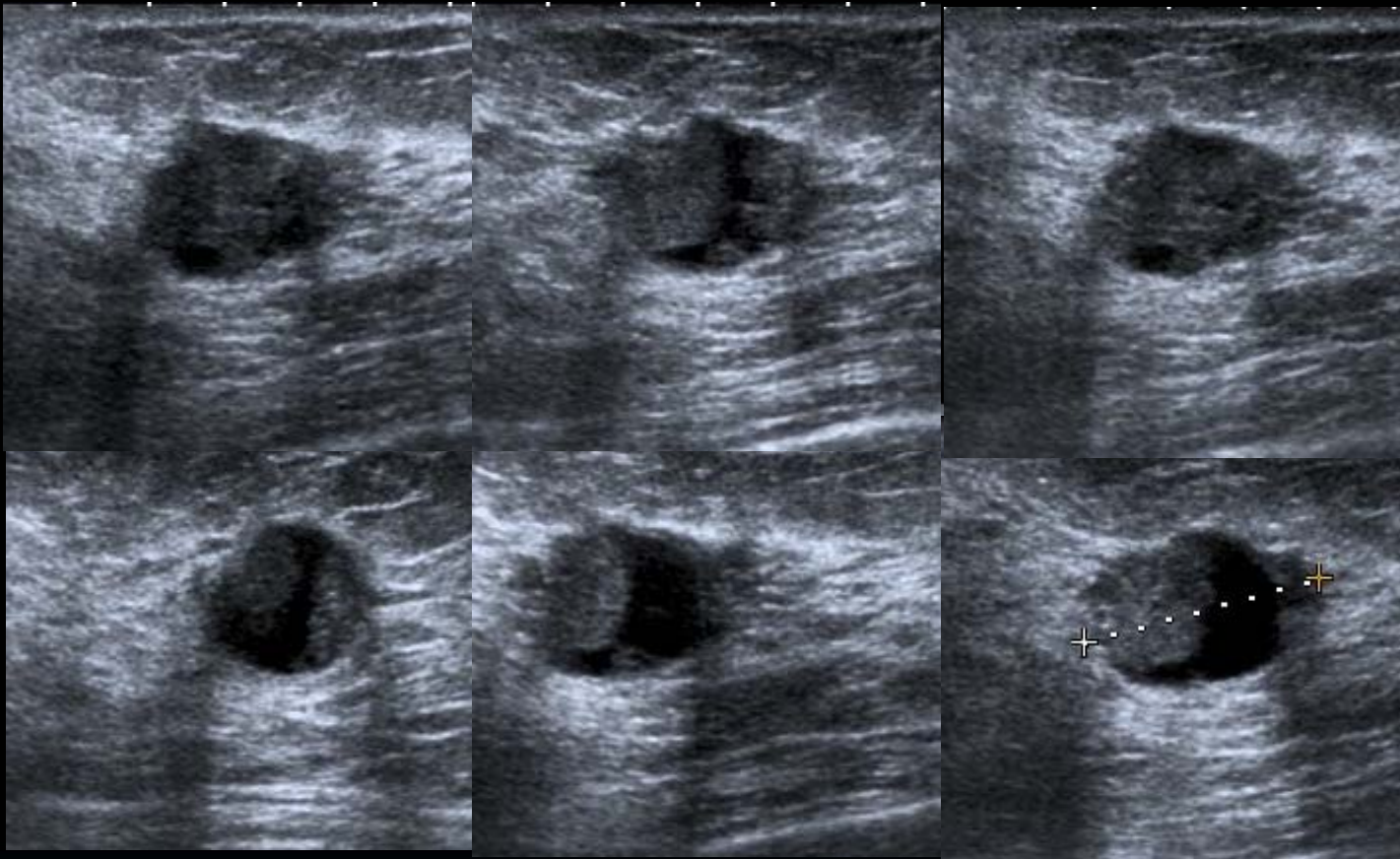
Approfondiamo?

- A) si
- B) no

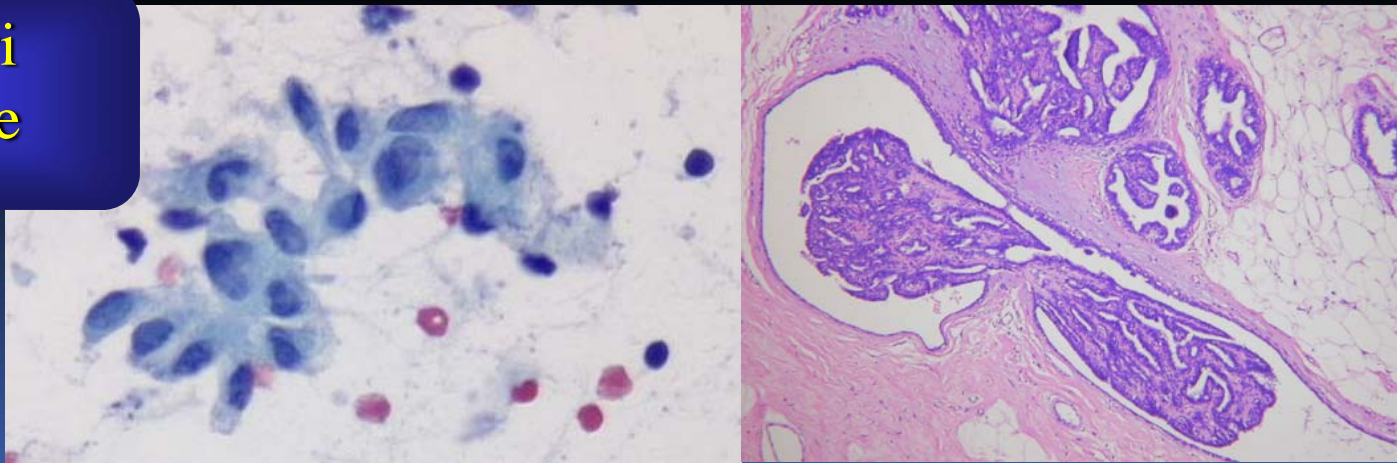
Come?

- A) Proiez. supplementare
- B) Compressione mirata
- C) Ingrandimento
- D) Ecografia



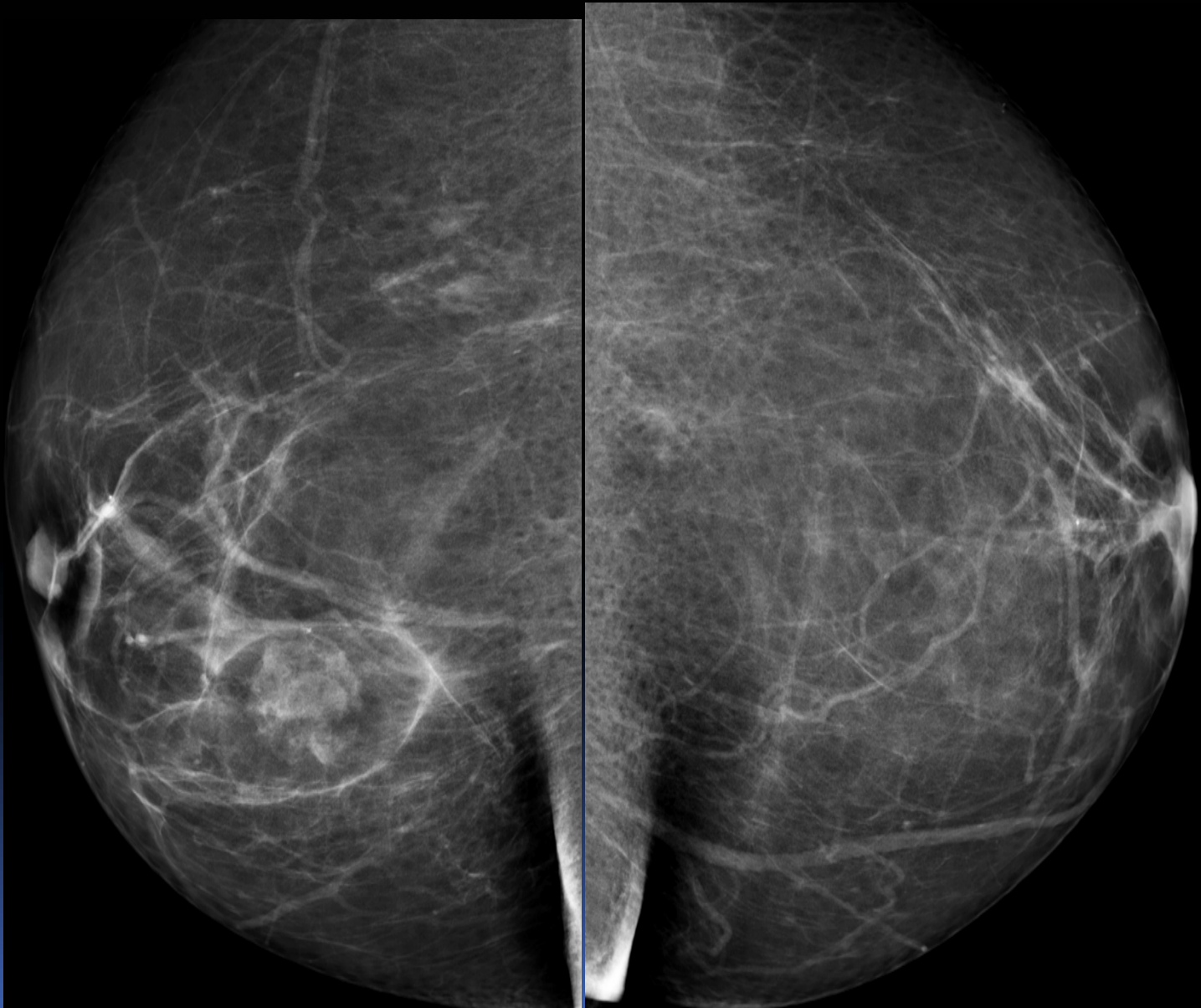


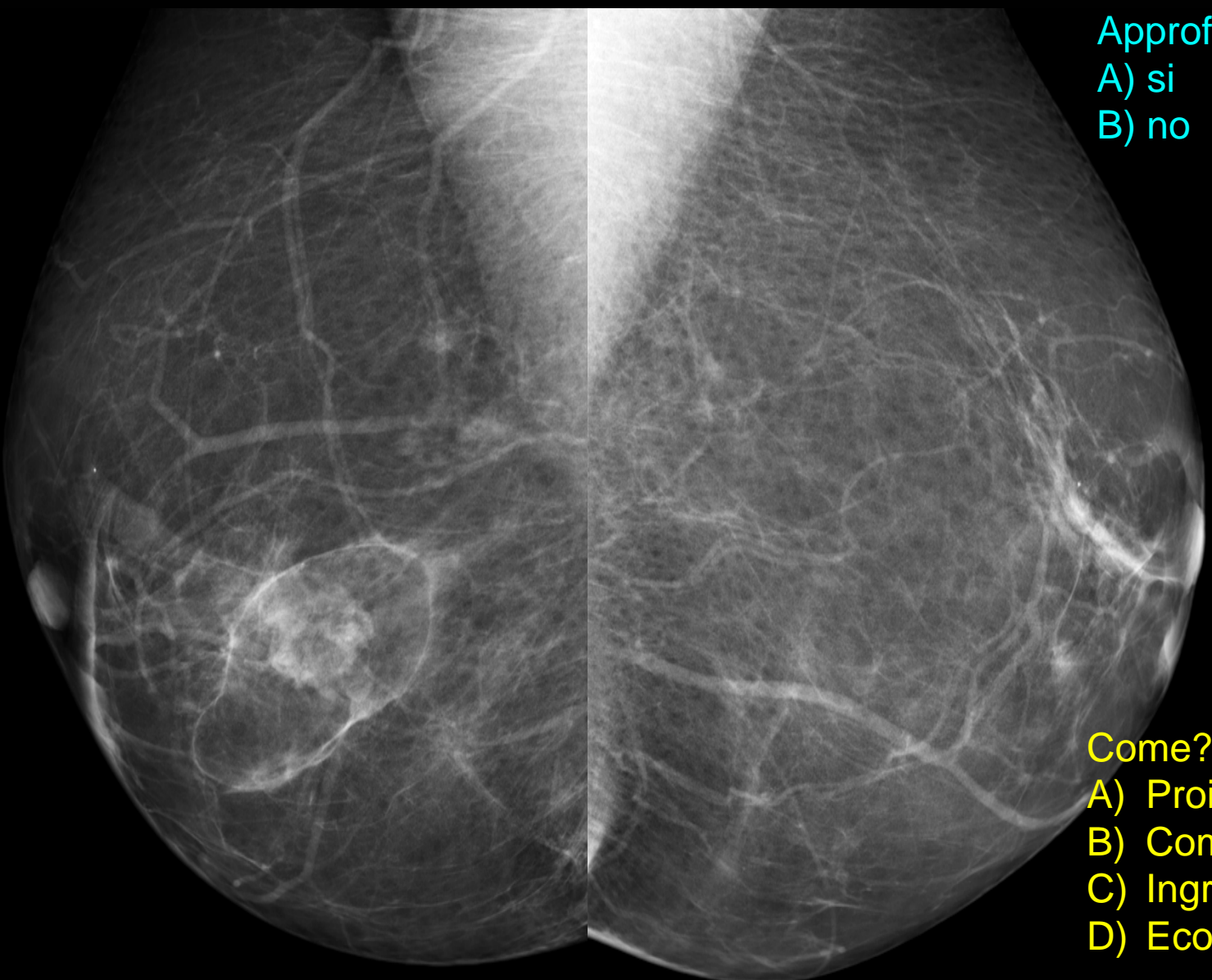
Lievi
atipie



CASO 12

- 55 aa
- Mastoplastica riduttiva 4 aa prima



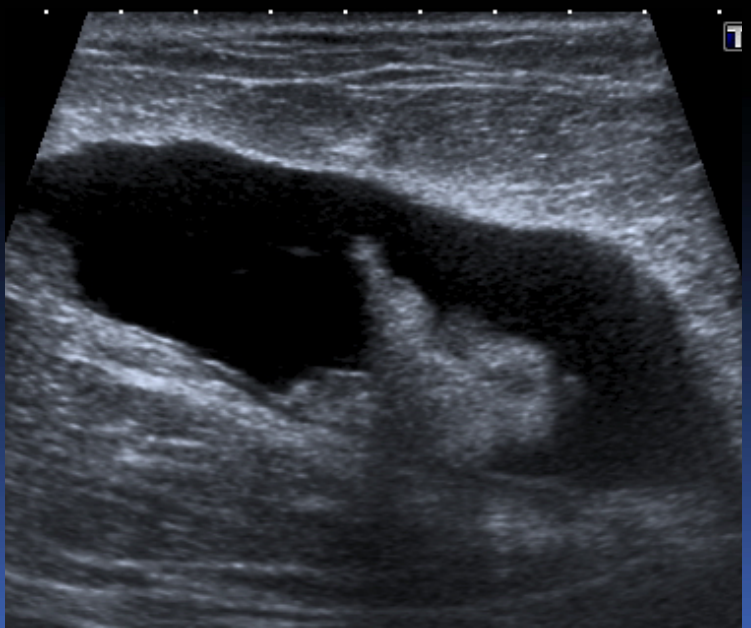
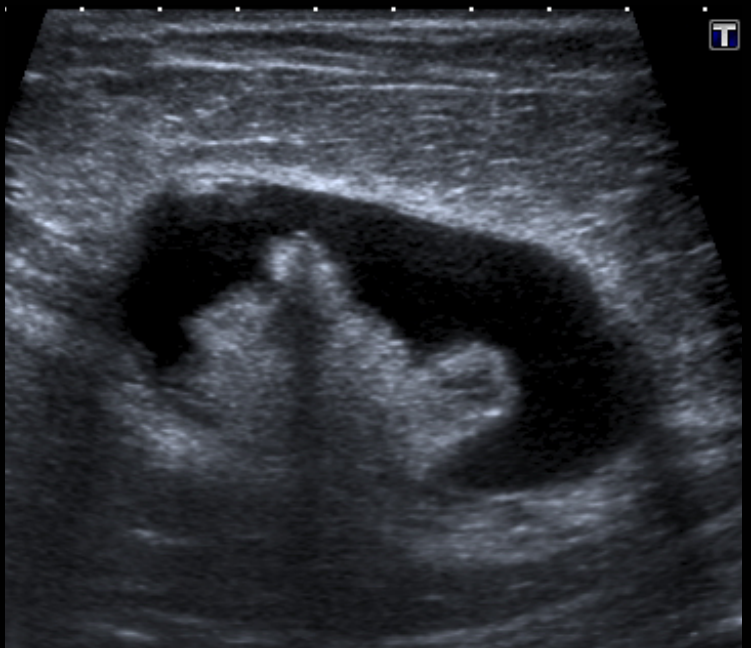
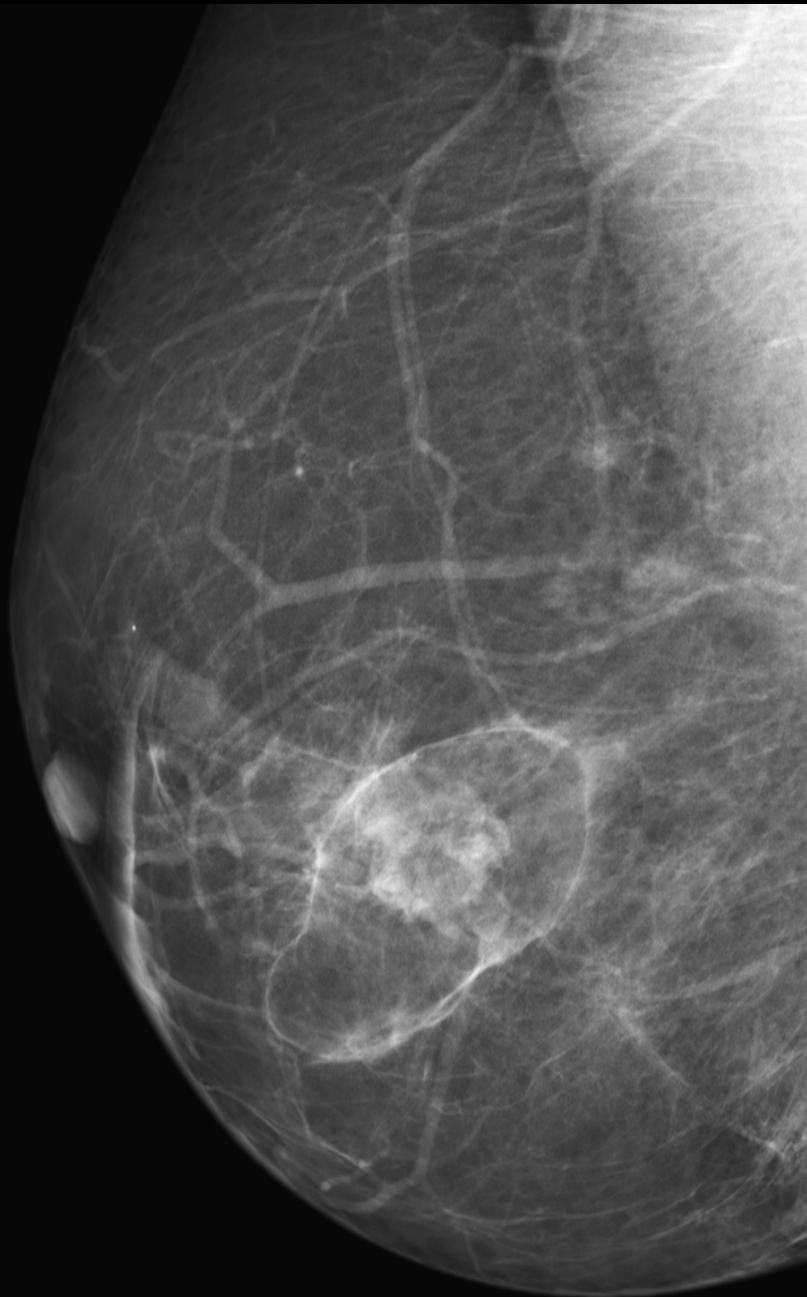


Approfondiamo?

- A) si
- B) no

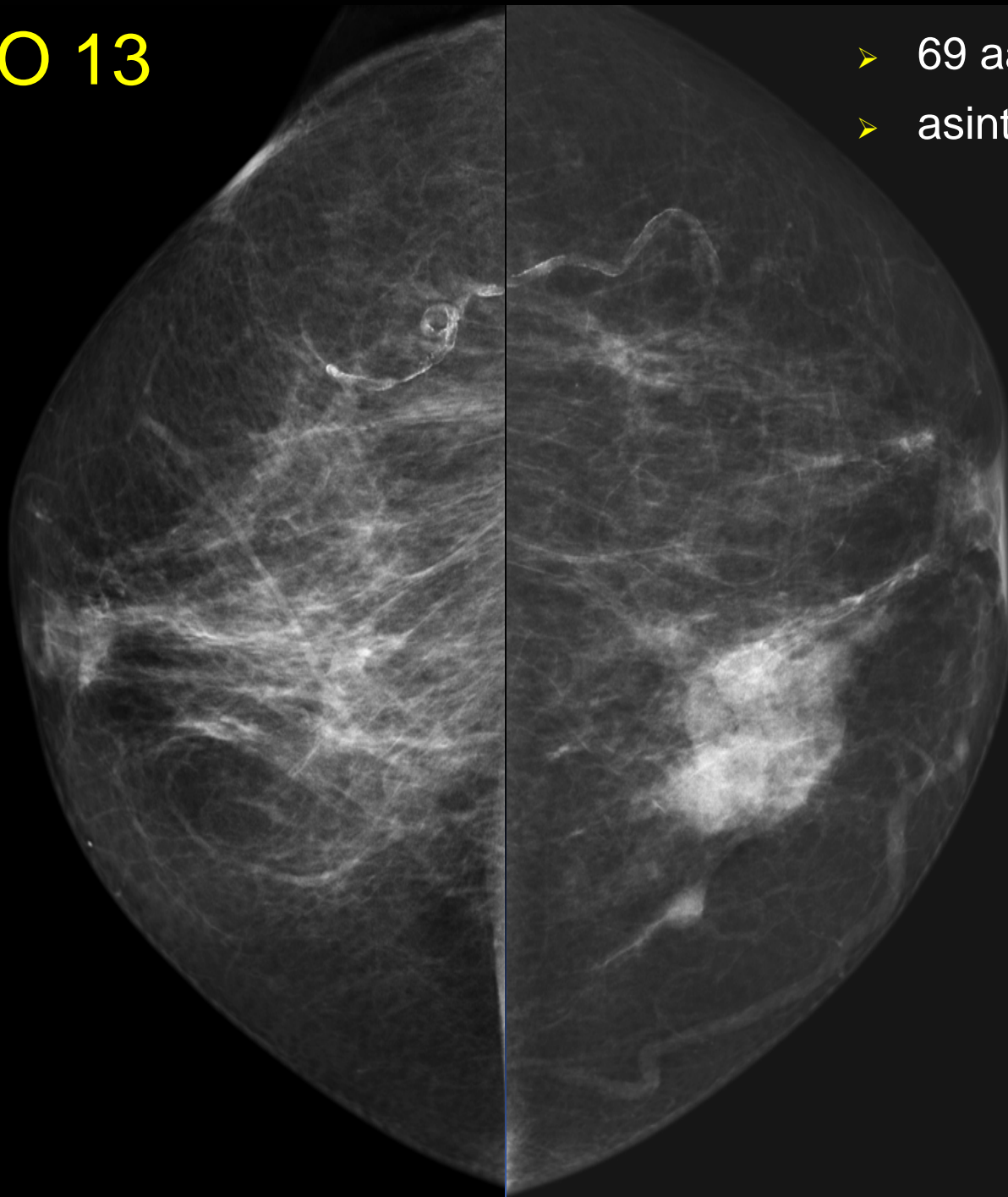
Come?

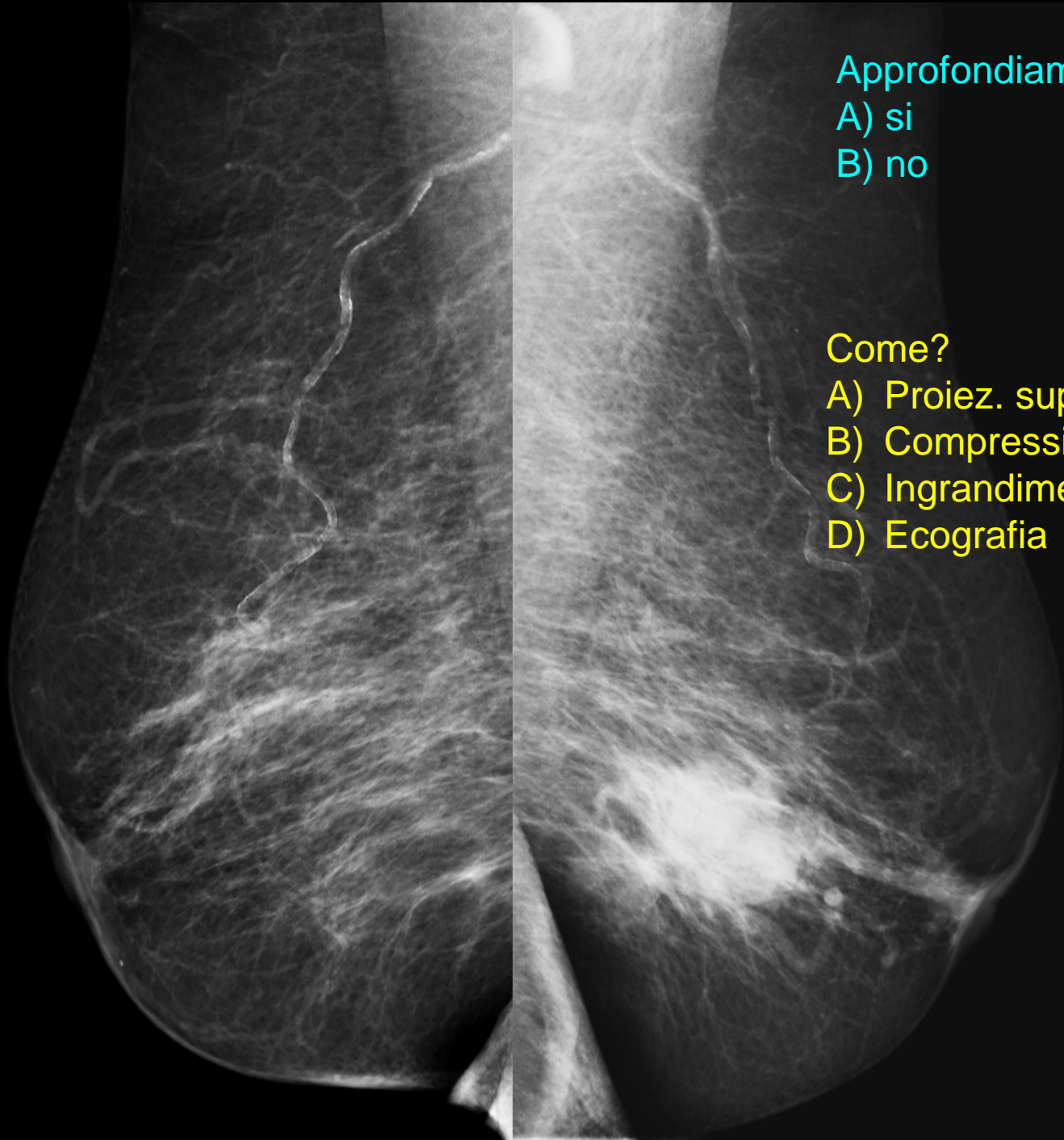
- A) Proiez. supplementare
- B) Compressione mirata
- C) Ingrandimento
- D) Ecografia



CASO 13

- 69 aa
- asintomatica





Approfondiamo?

A) si

B) no

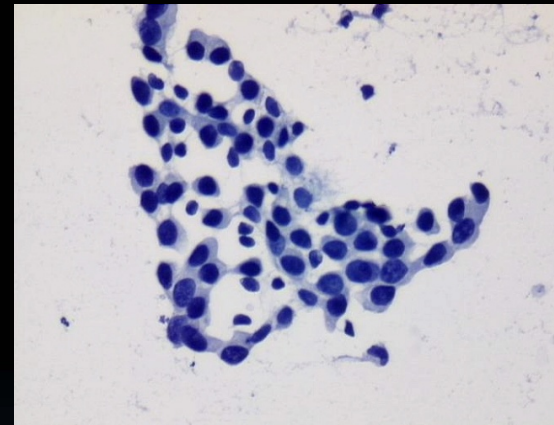
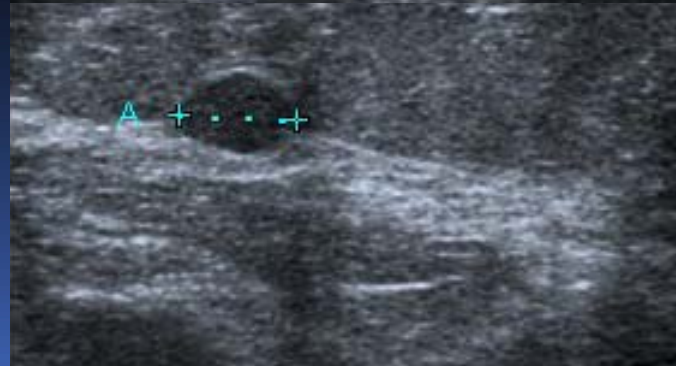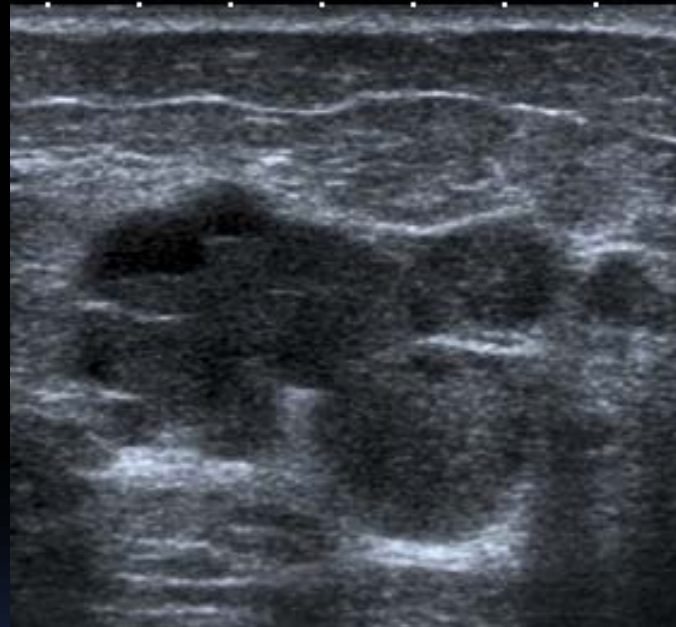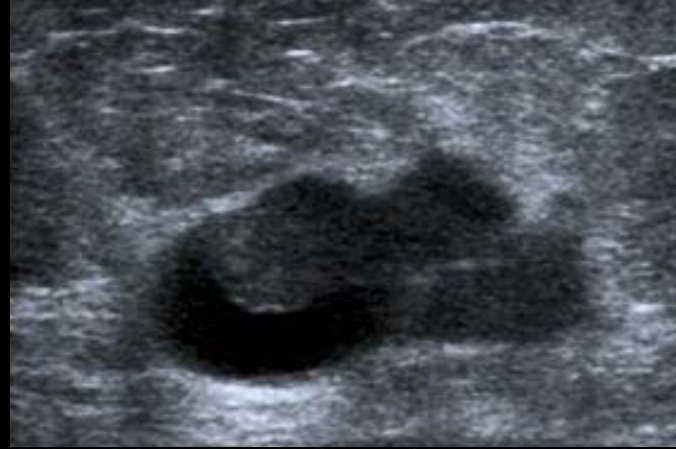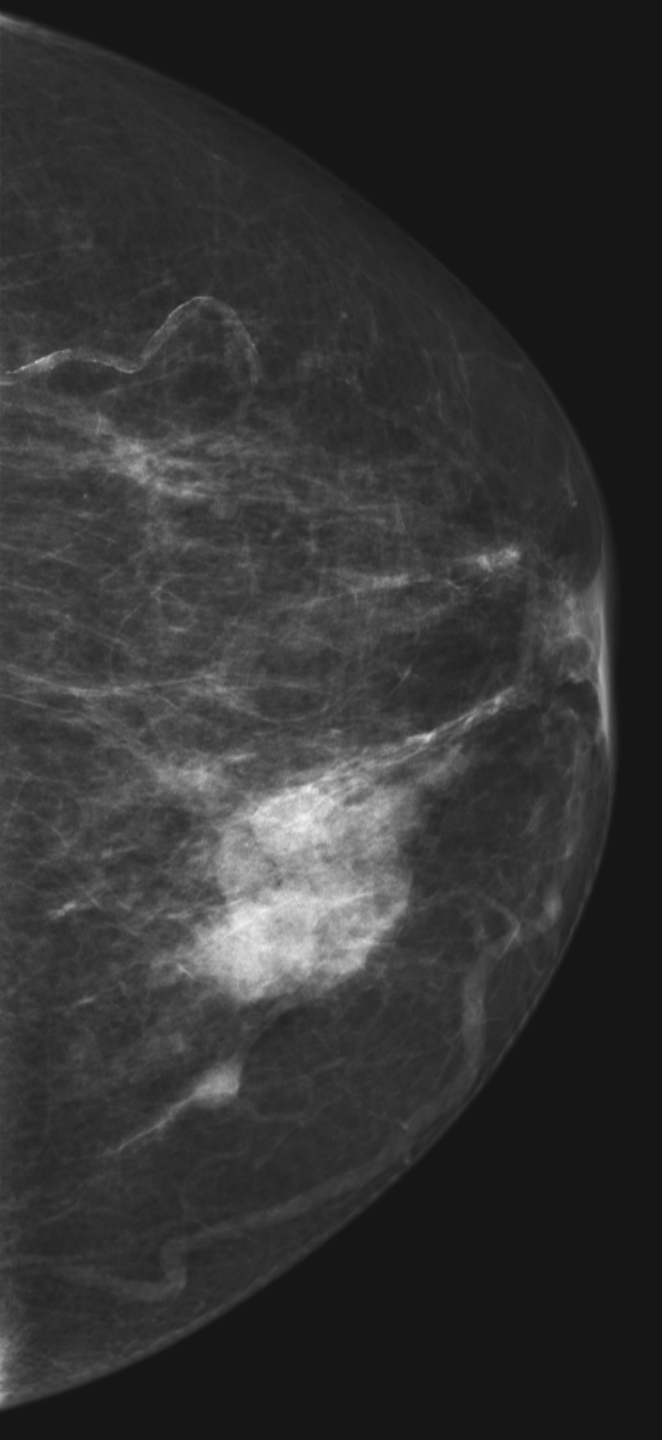
Come?

A) Proiez. supplementare

B) Compressione mirata

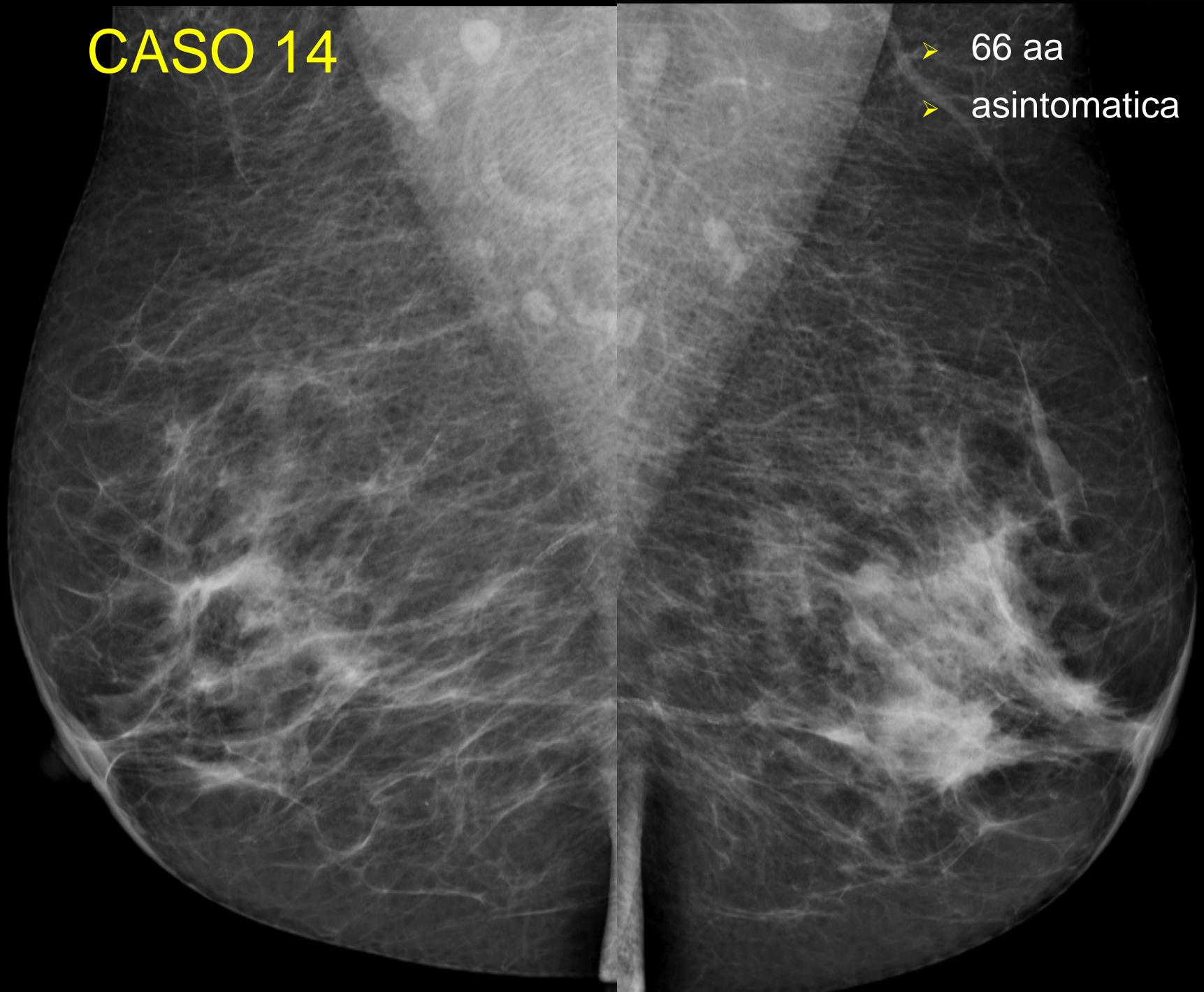
C) Ingrandimento

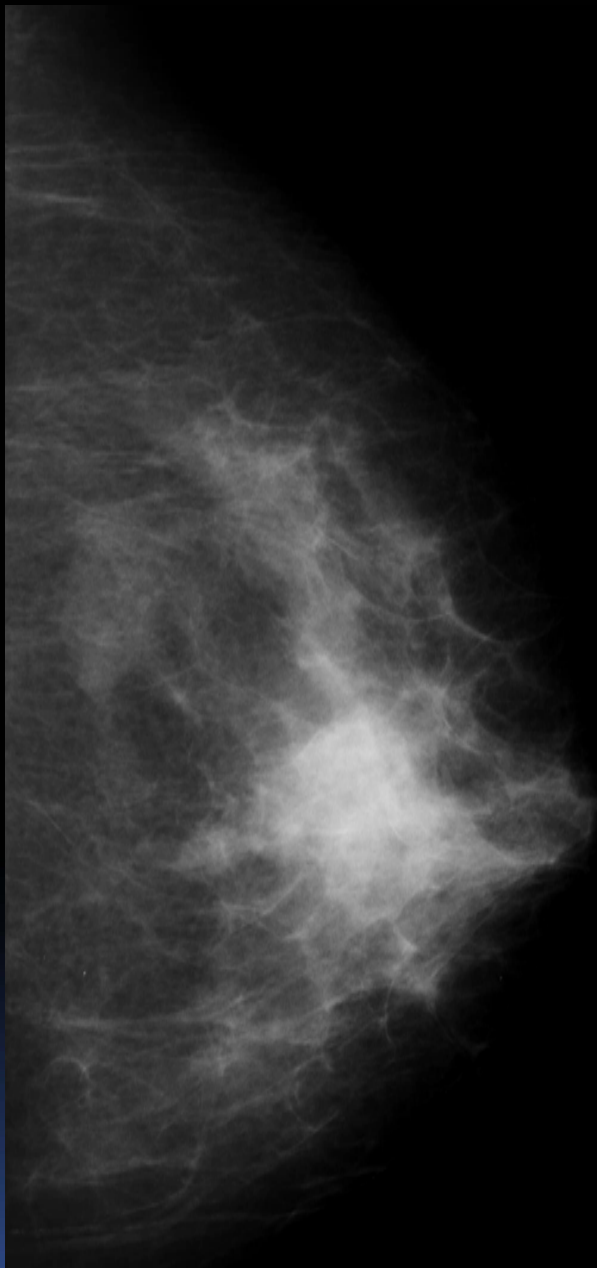
D) Ecografia



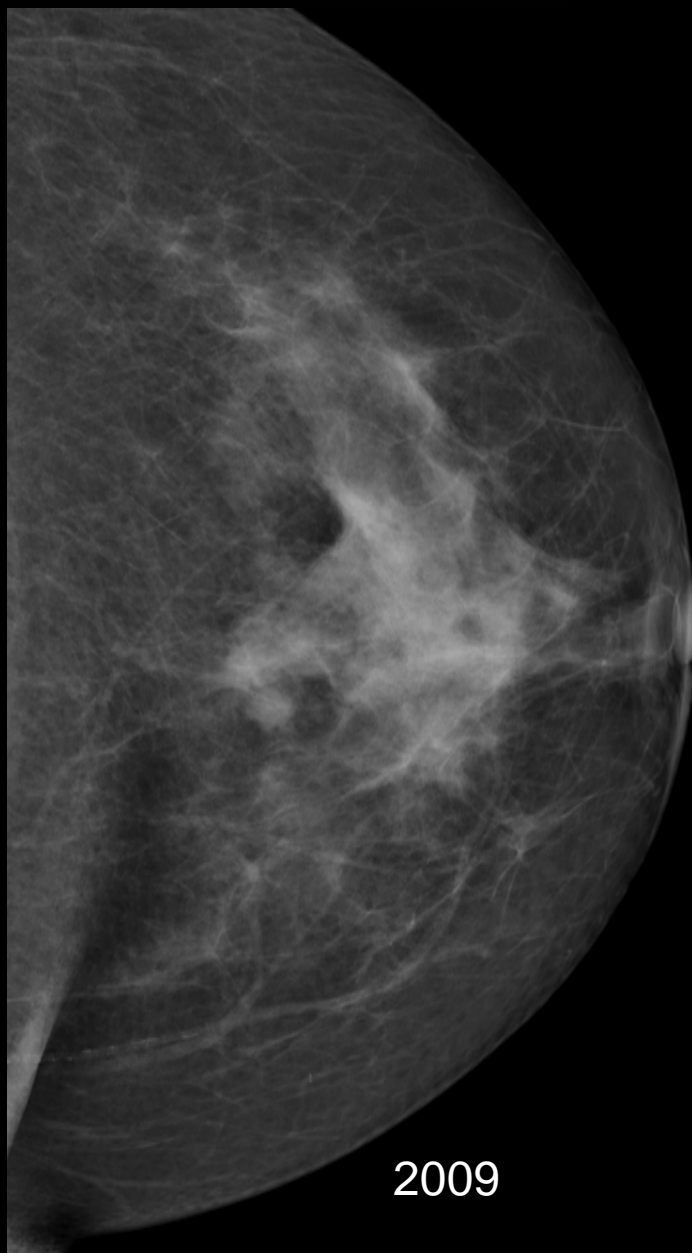
CASO 14

- 66 aa
- asintomatica





2005



2009

Approfondiamo?

A) si

B) no

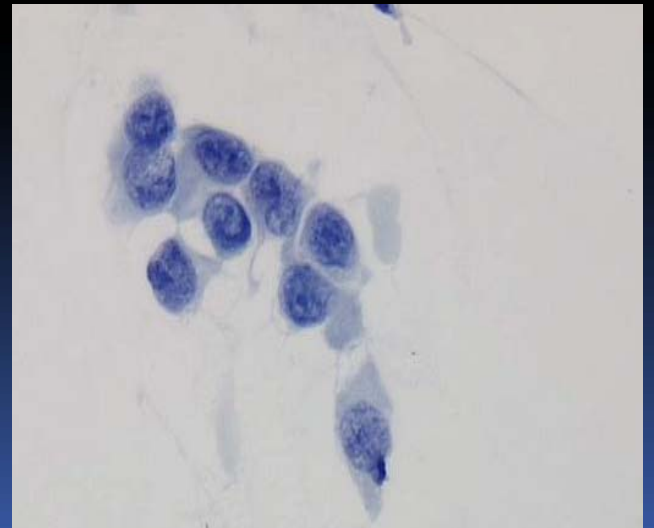
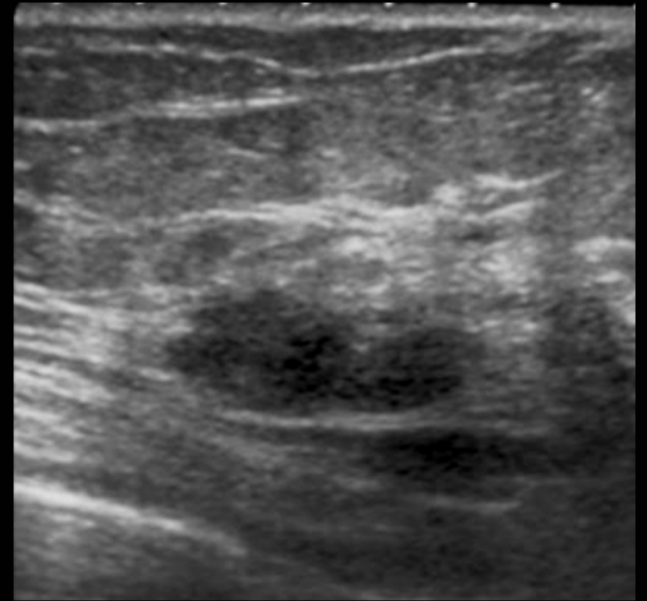
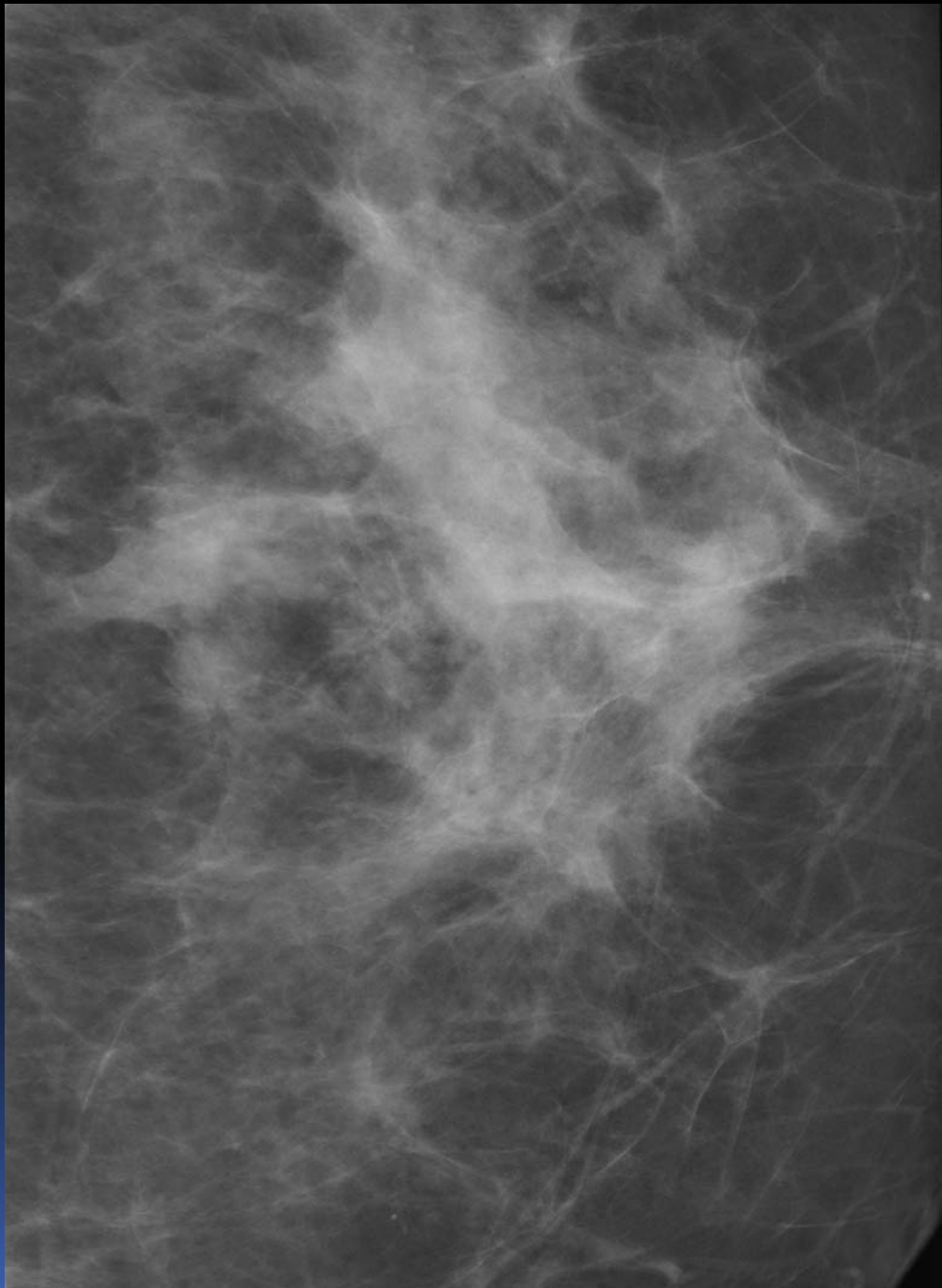
Come?

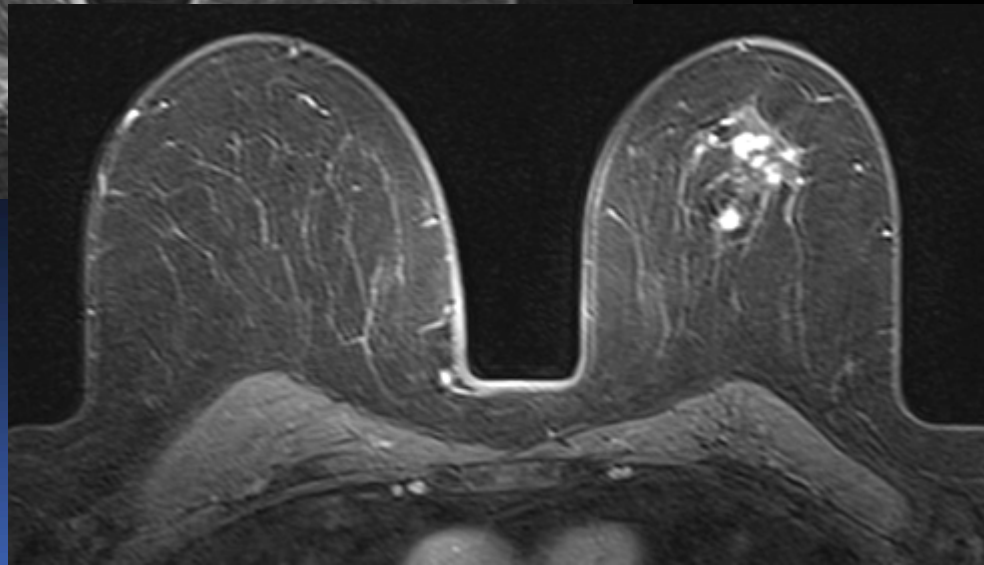
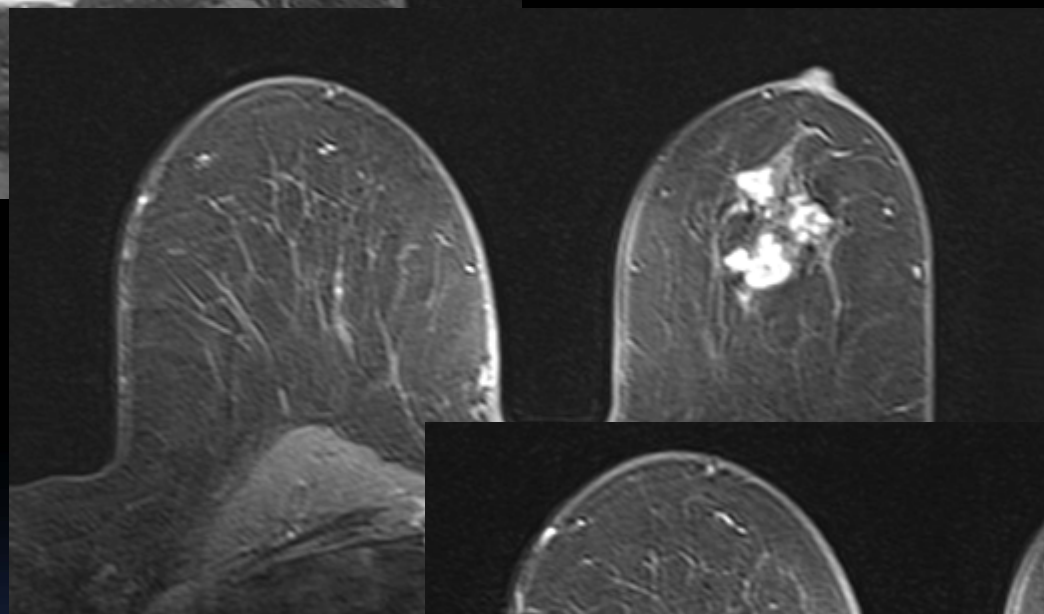
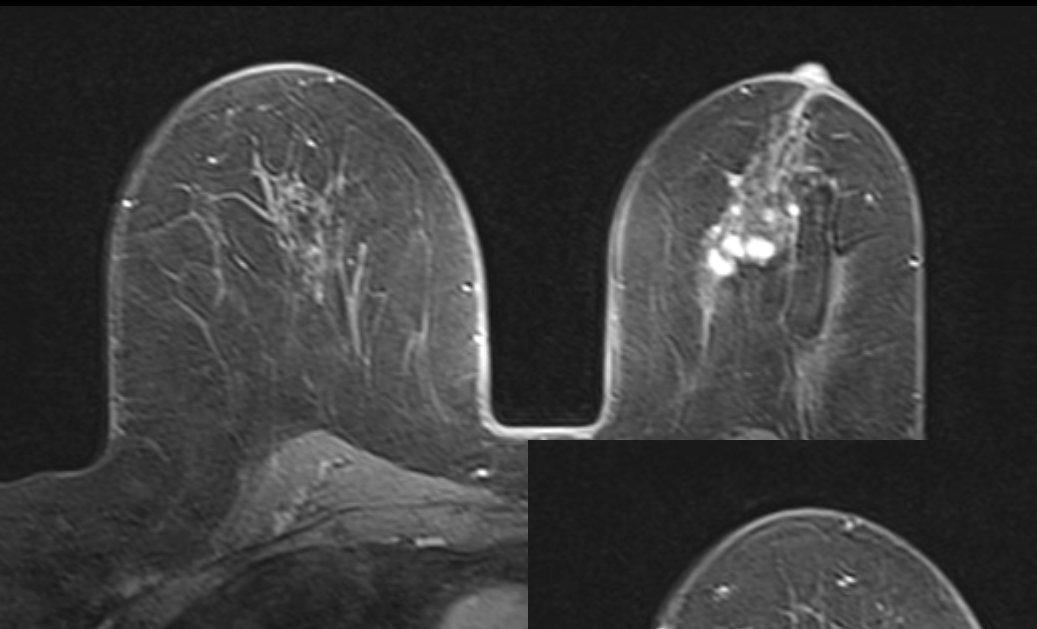
A) Proiez. supplementare

B) Compressione mirata

C) Ingrandimento

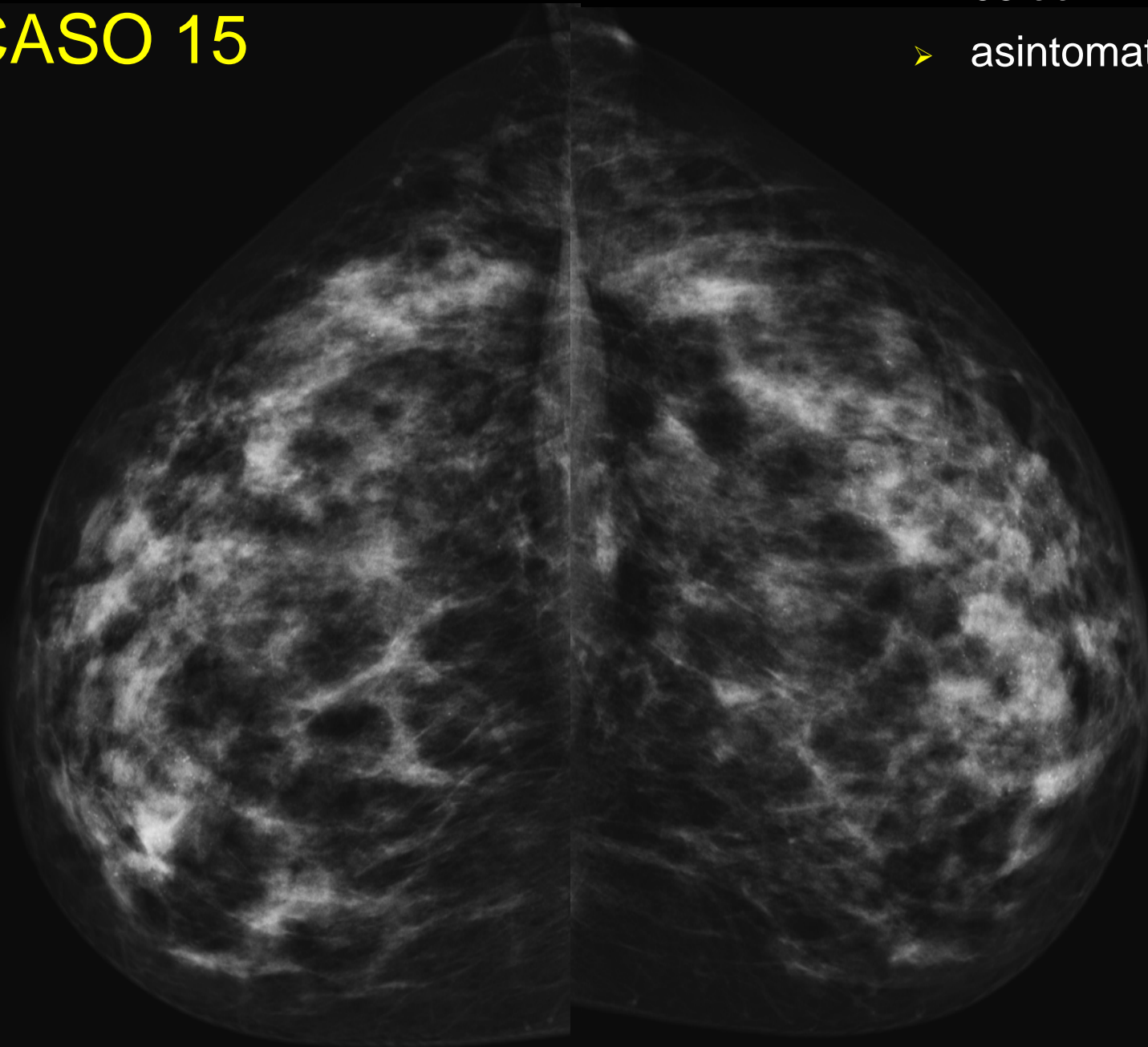
D) Ecografia

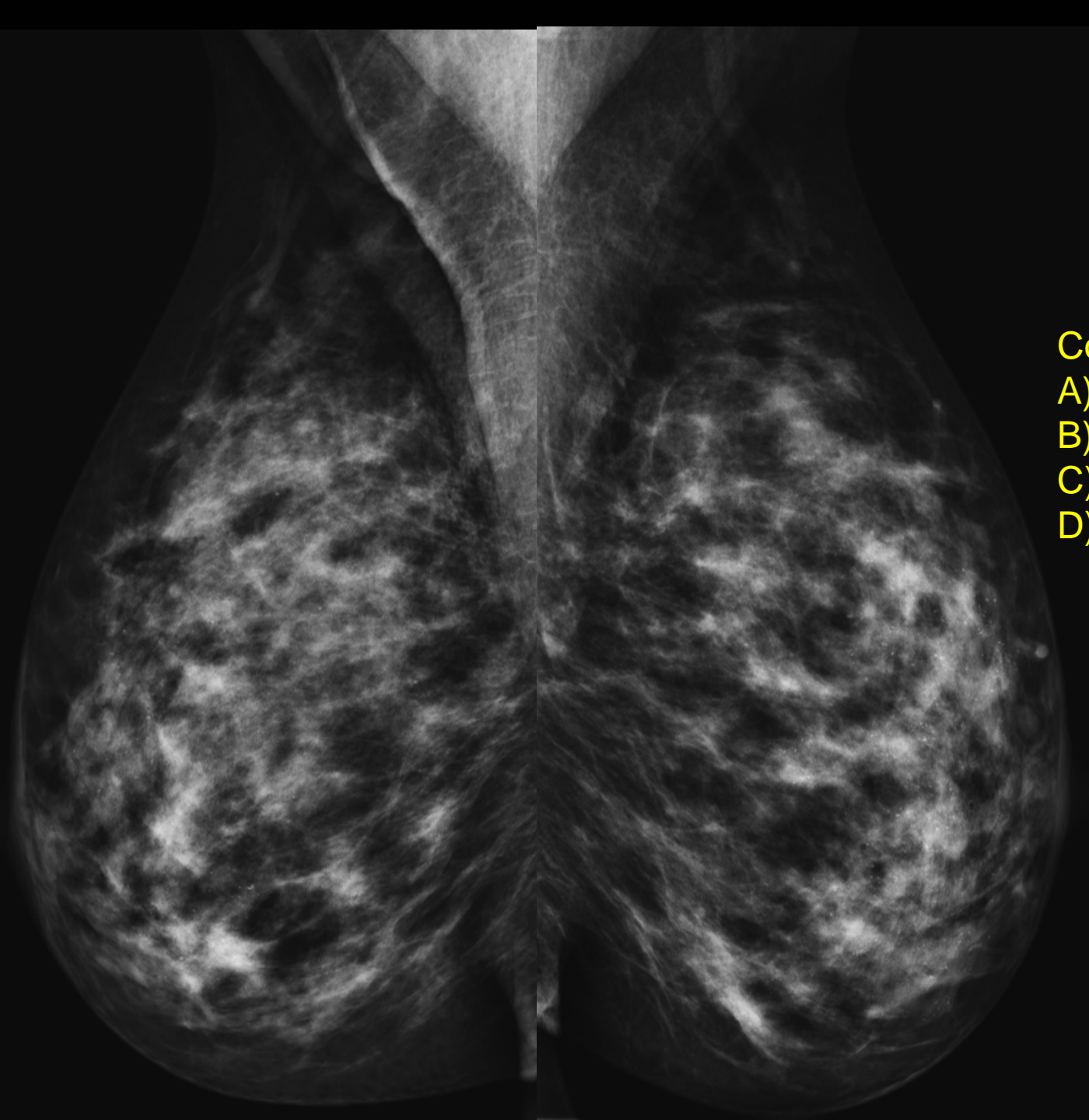




CASO 15

- 68 aa
- asintomatica





Approfondiamo?

A) si

B) no

Come?

A) Proiez. supplementare

B) Compressione mirata

C) Ingrandimento

D) Ecografia

Dove?

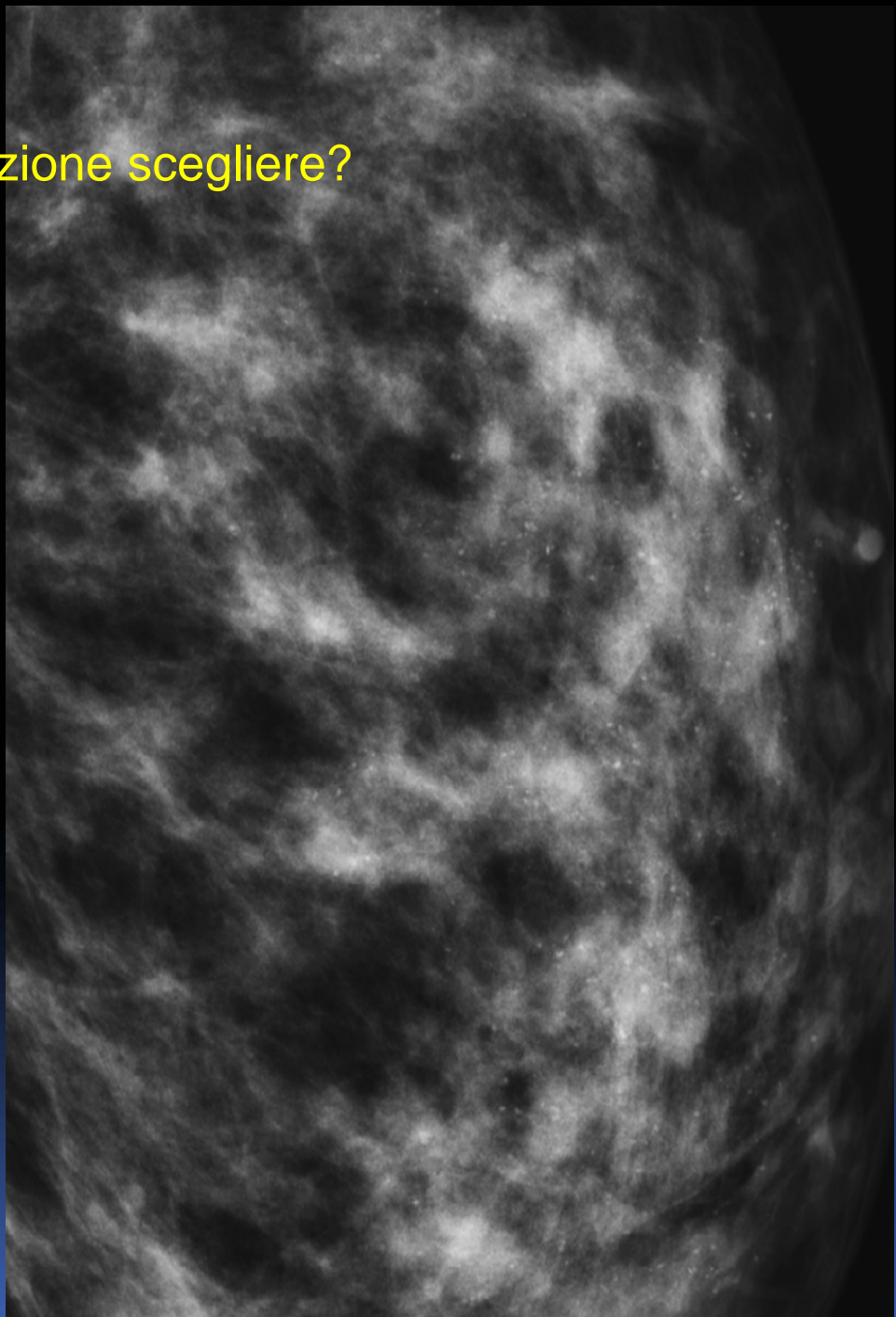
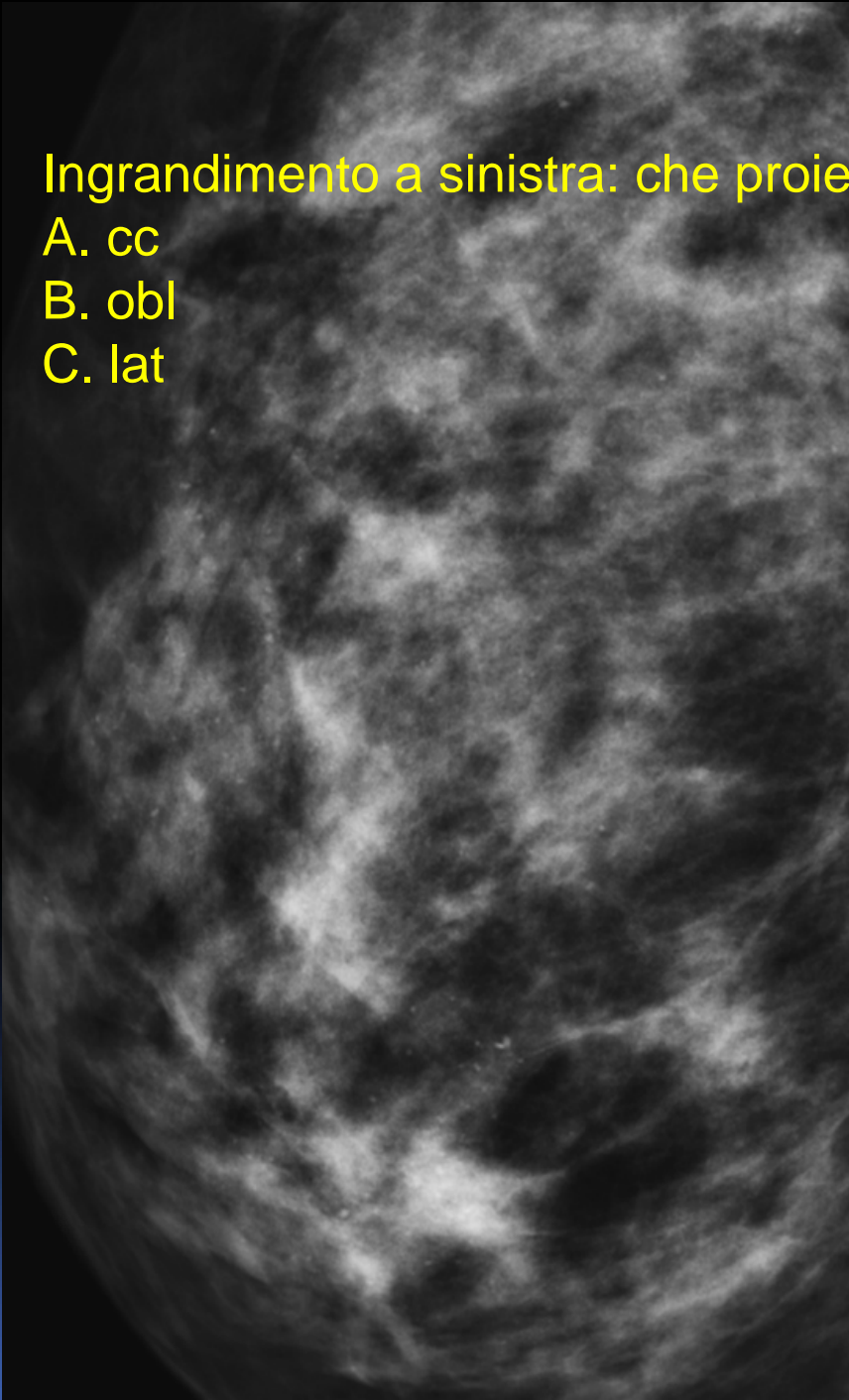
A) DX

B) SN

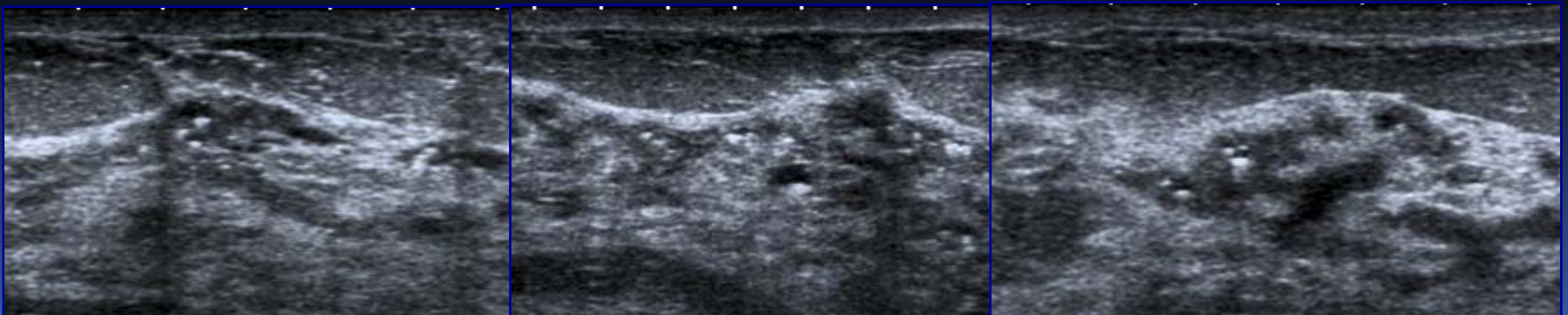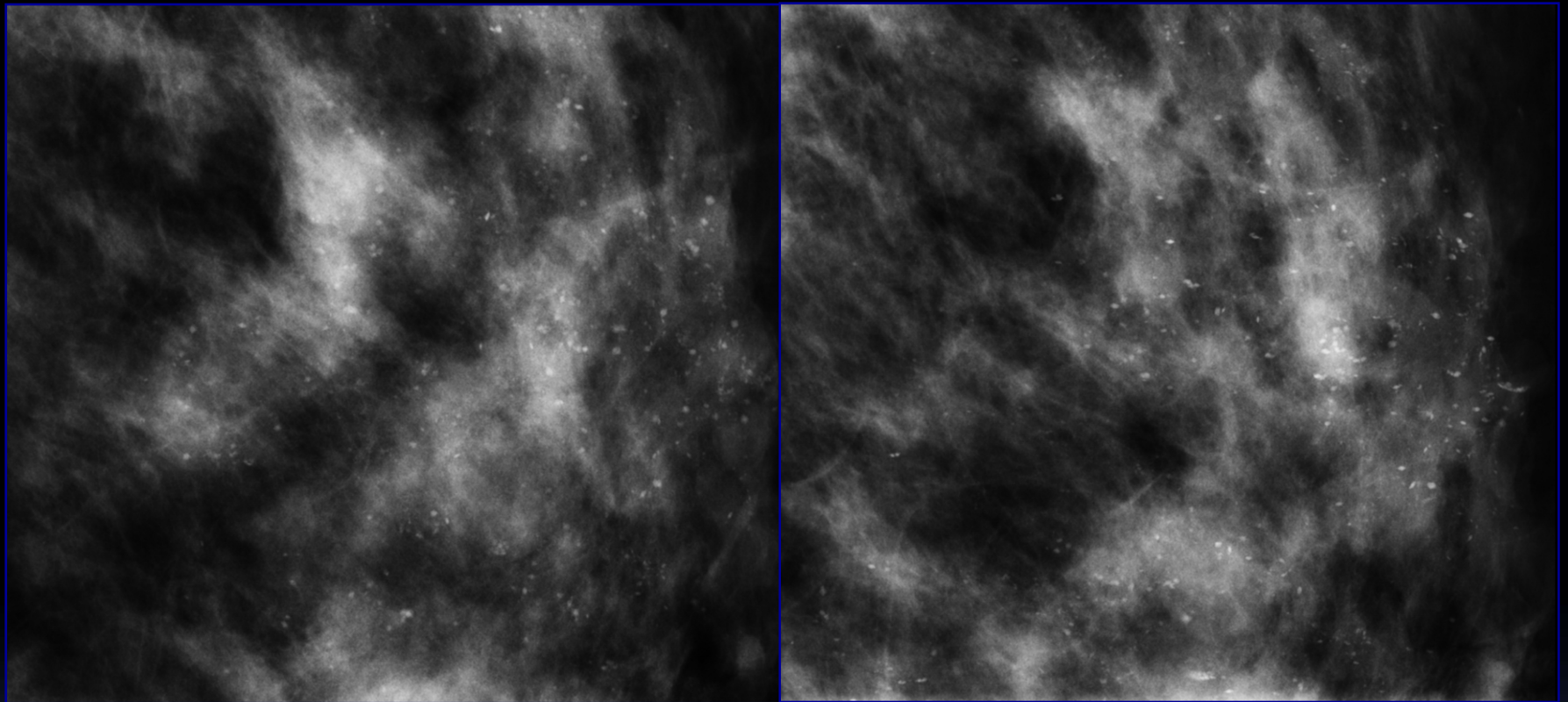
C) DX e SN

Ingrandimento a sinistra: che proiezione scegliere?

- A. cc
- B. obl
- C. lat

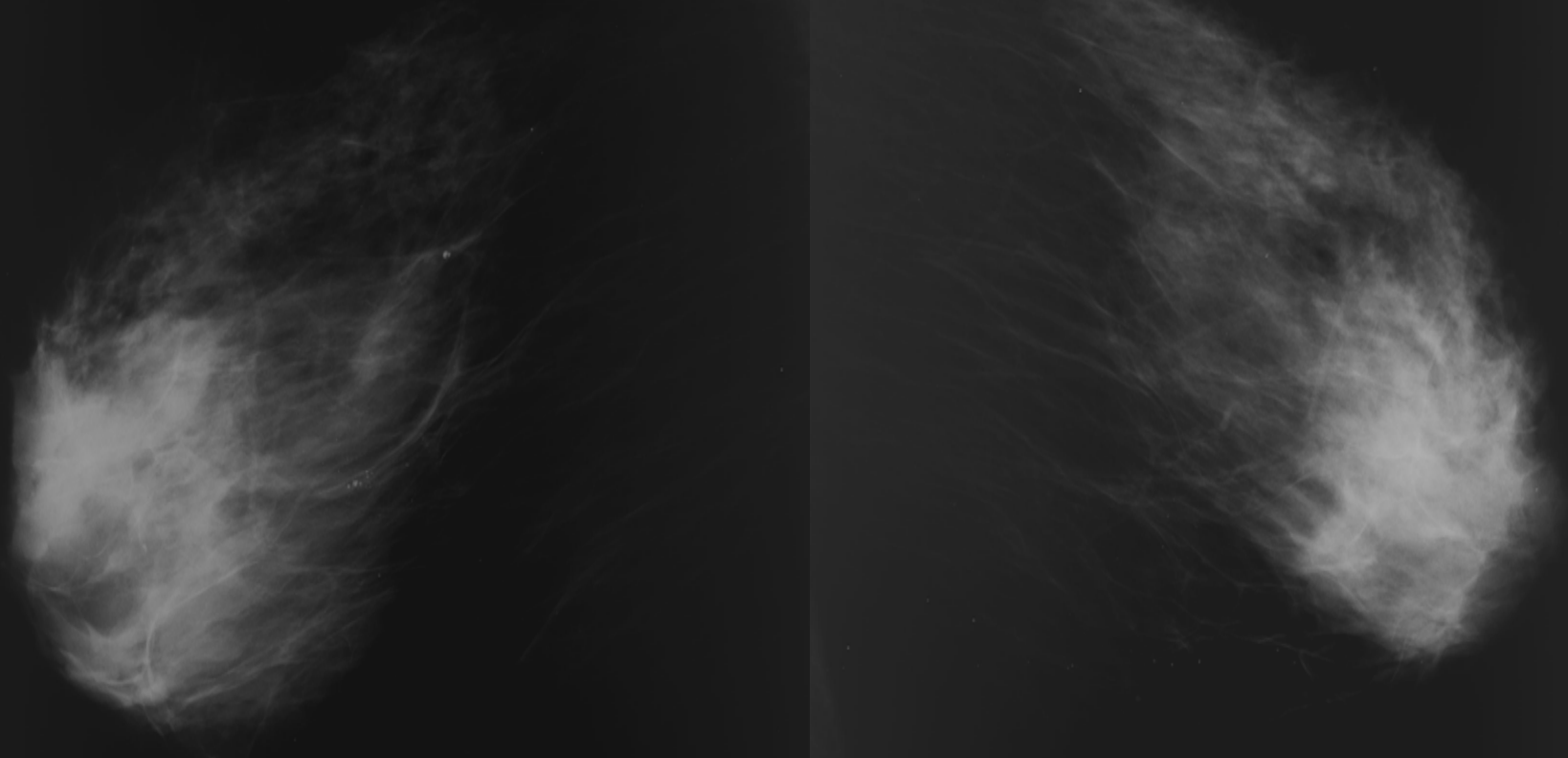


Risposta: C (Ingrandimento laterale)



CASO 16

- 54 aa
- asintomatica



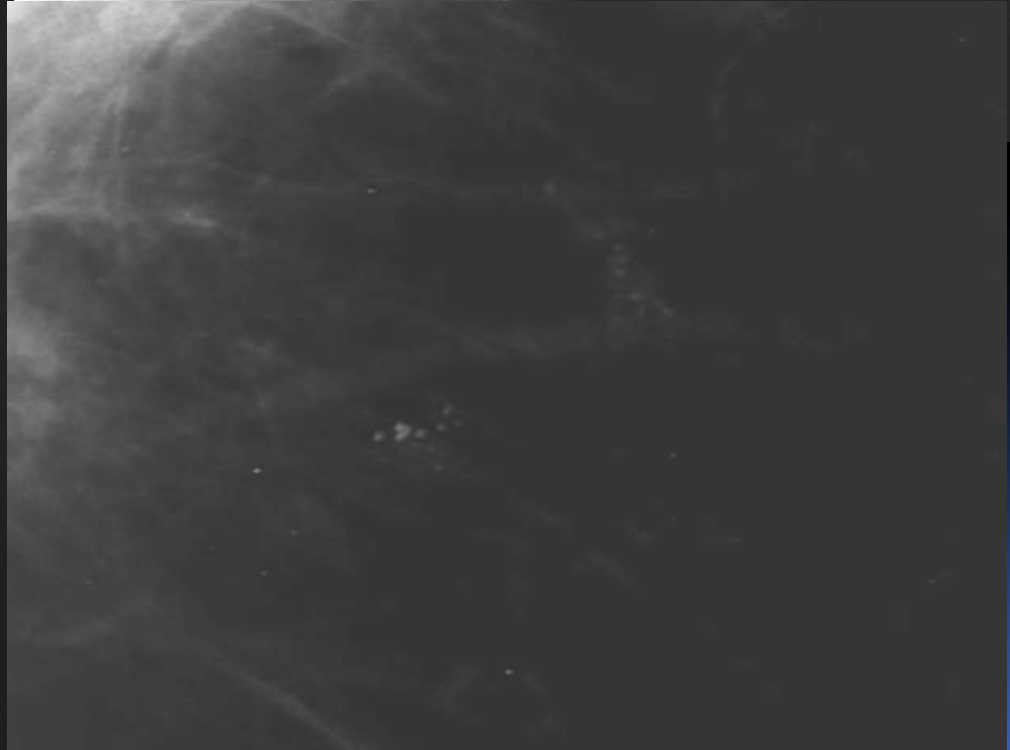
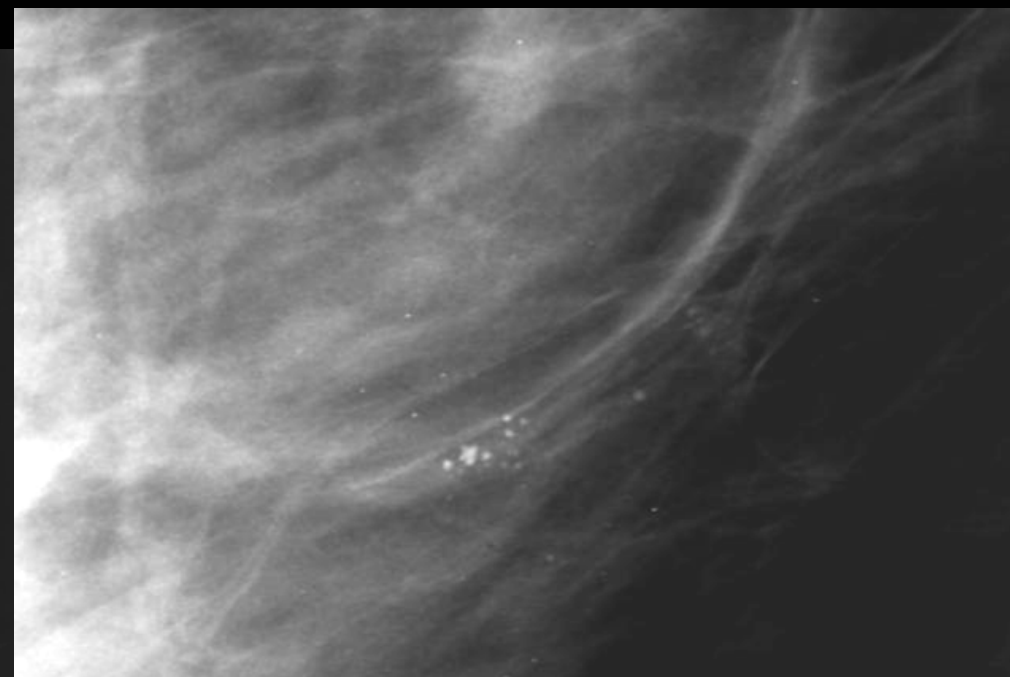
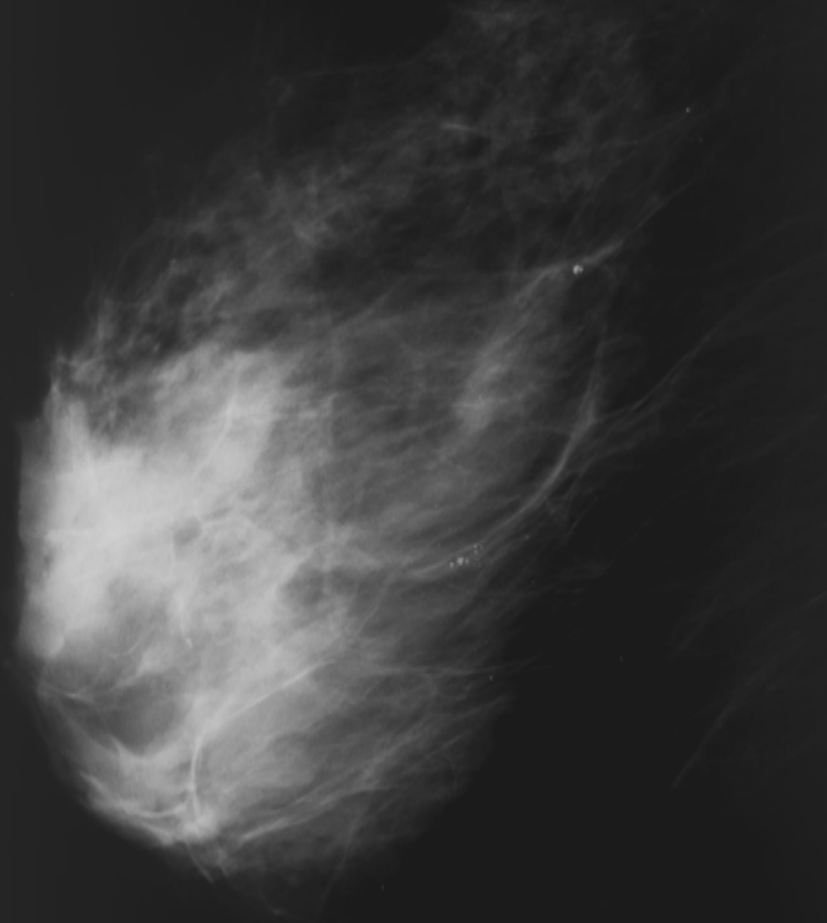
Iter successivo?

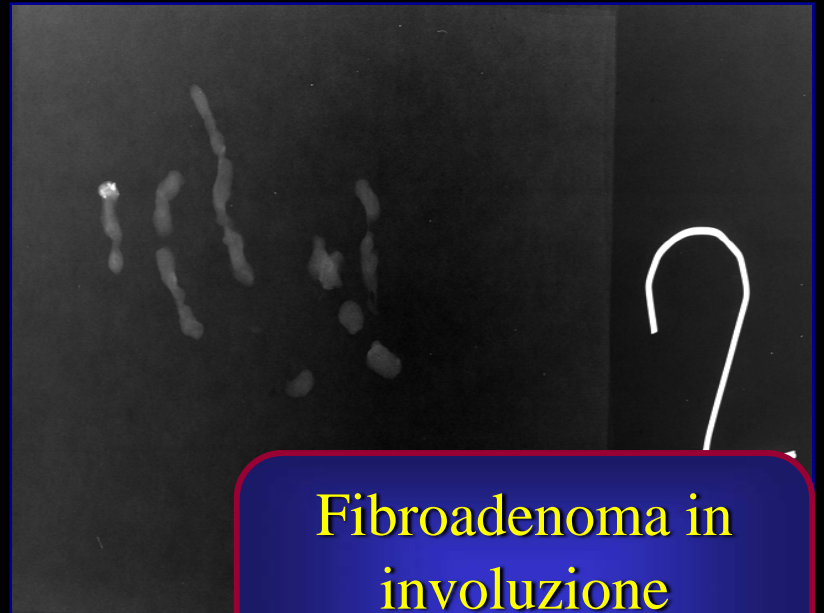
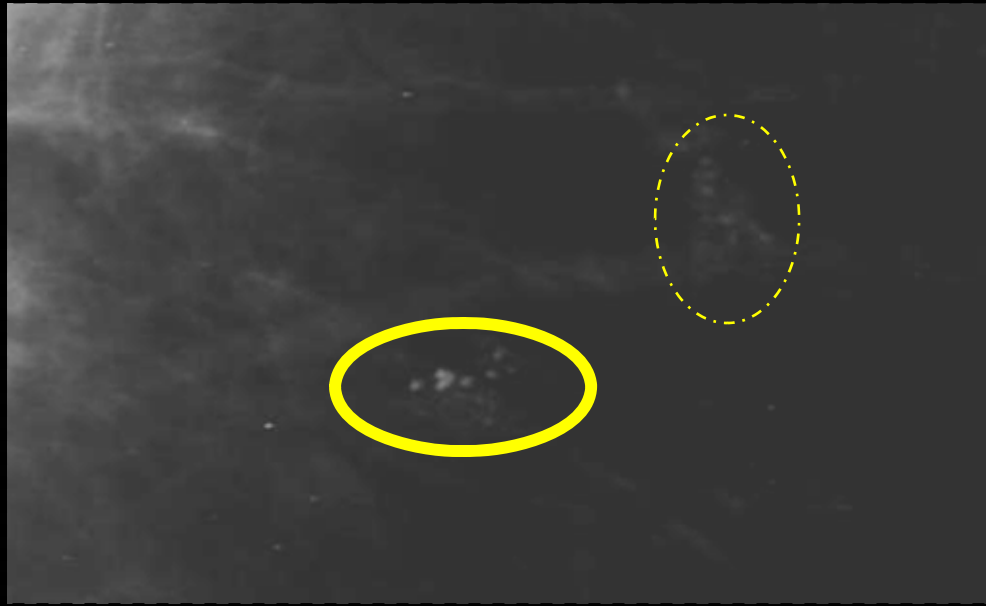
A) Follow-up

B) Agobiopsia

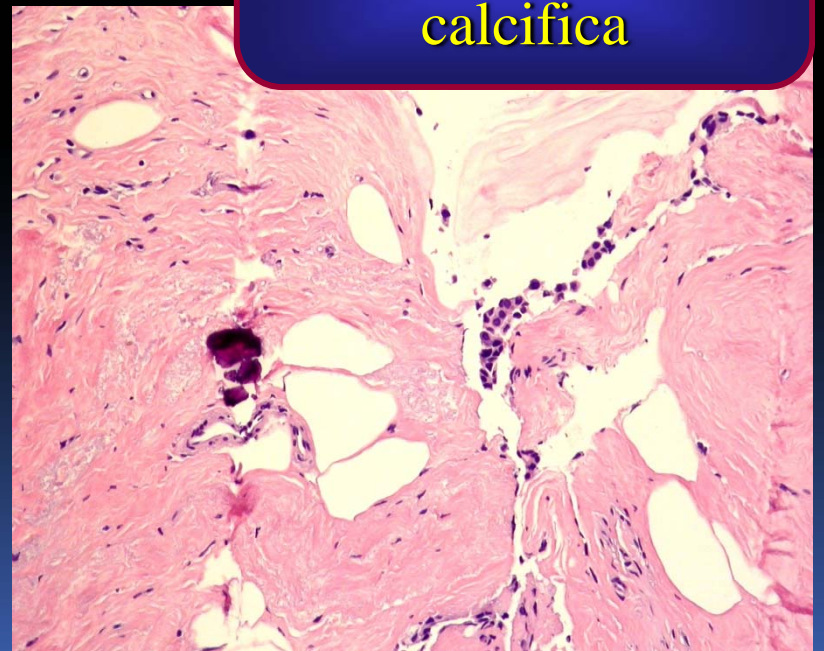
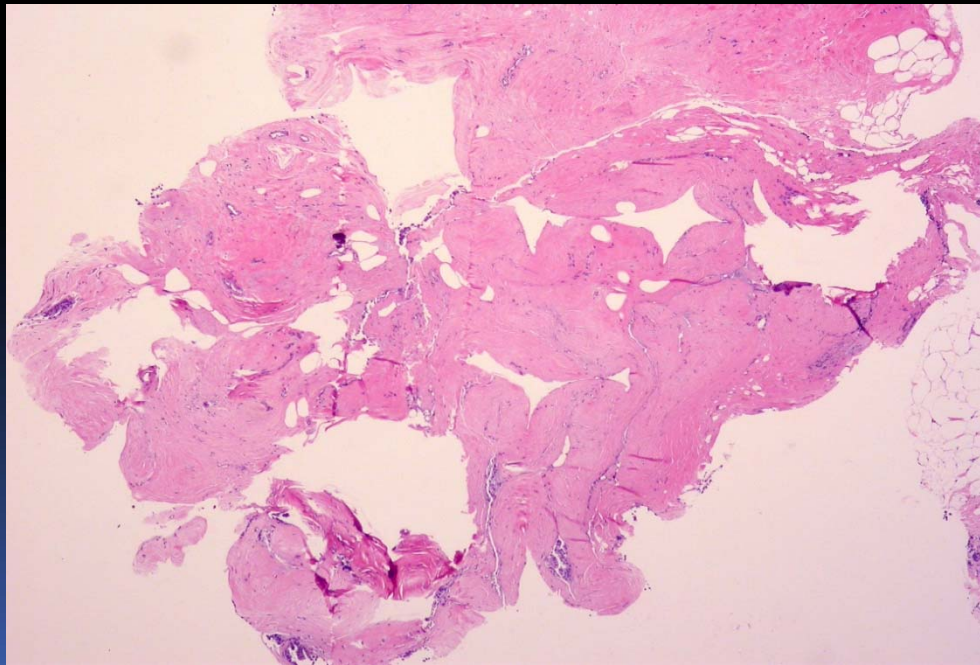
C) Core-biopsy

D) Microbiopsia vacuum assisted

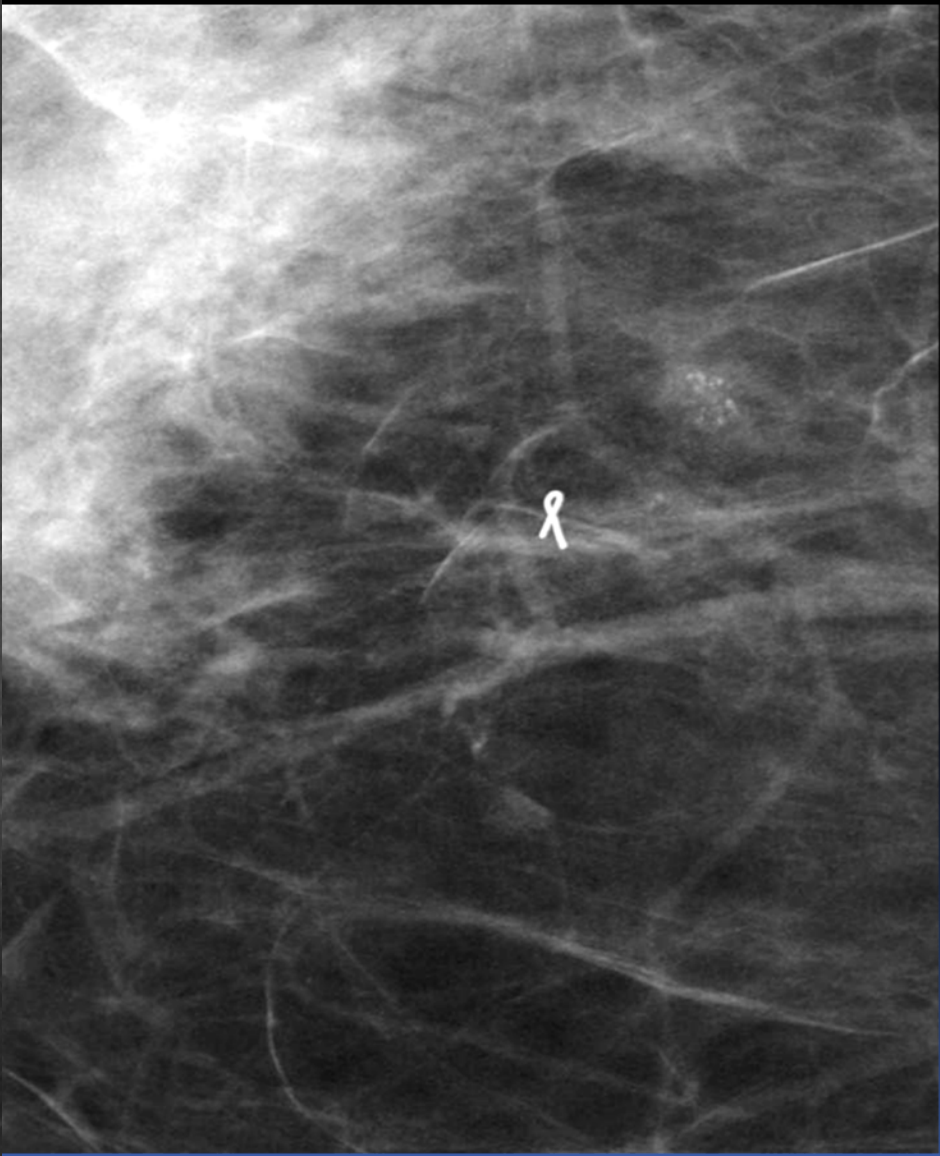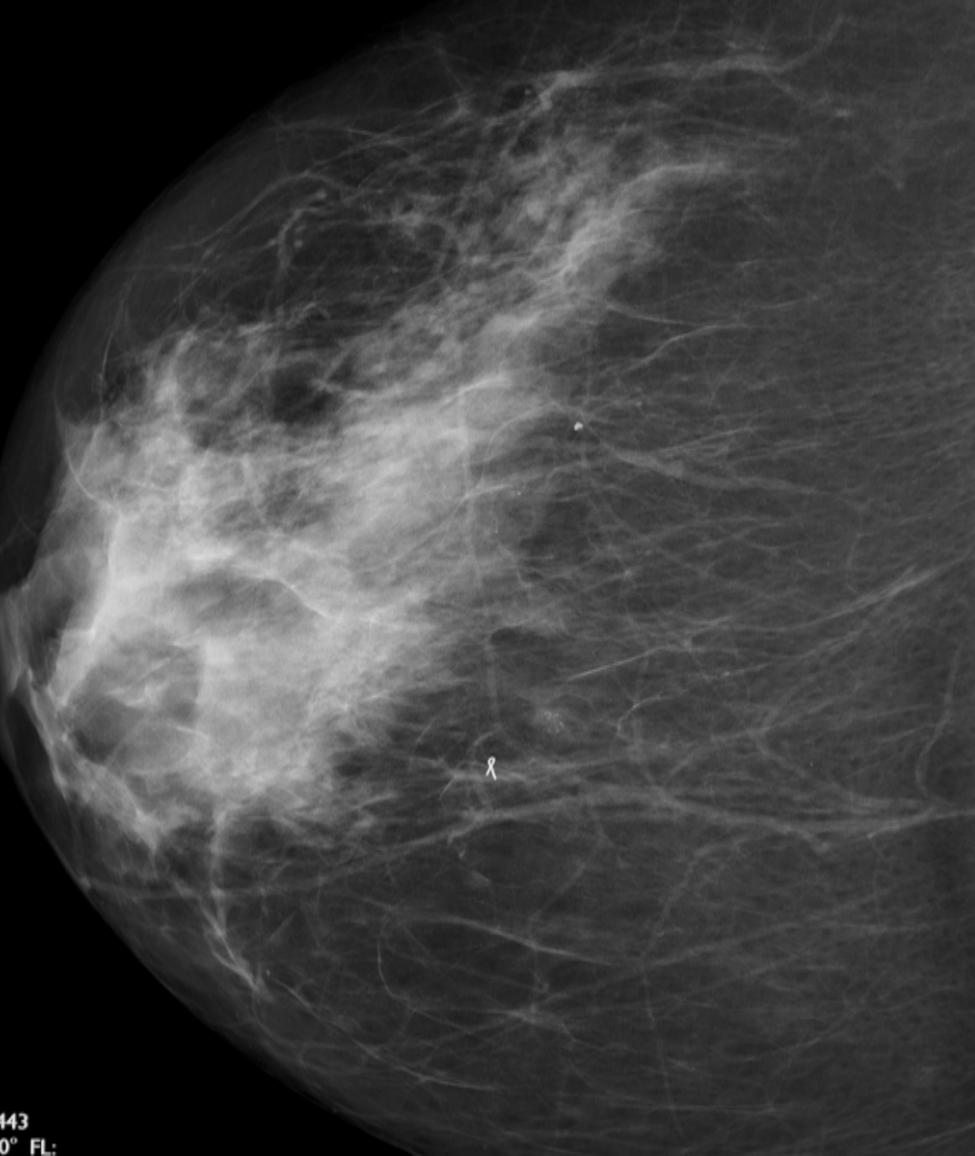


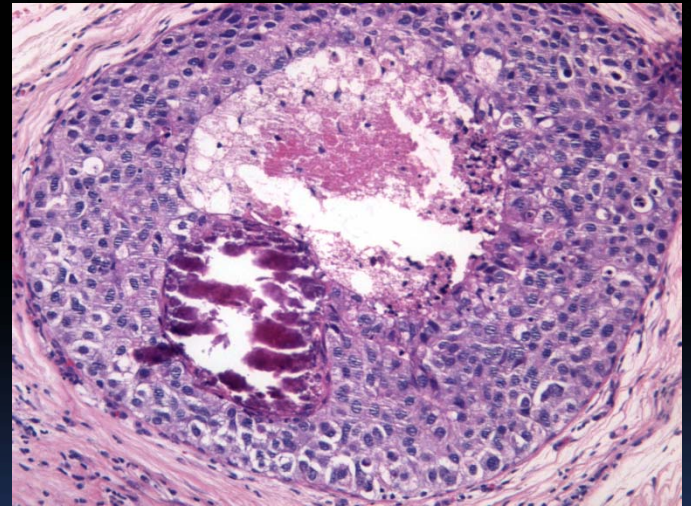
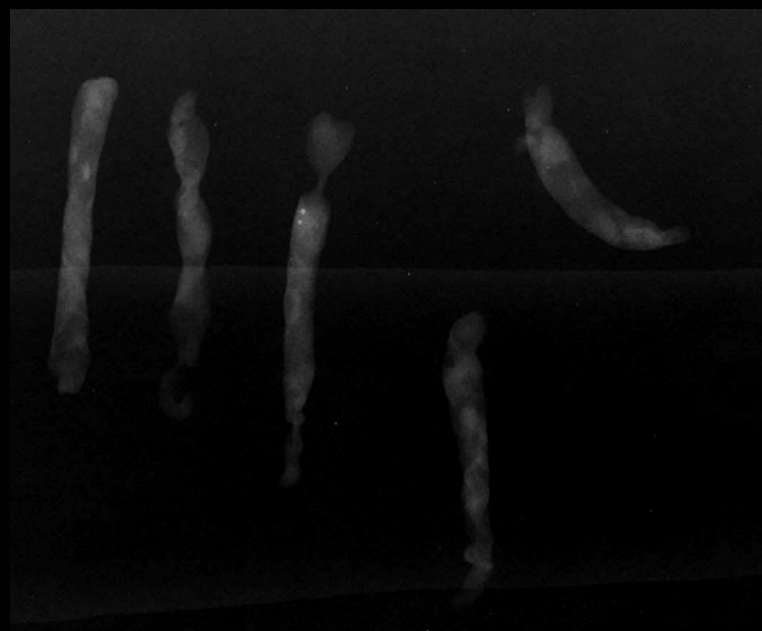
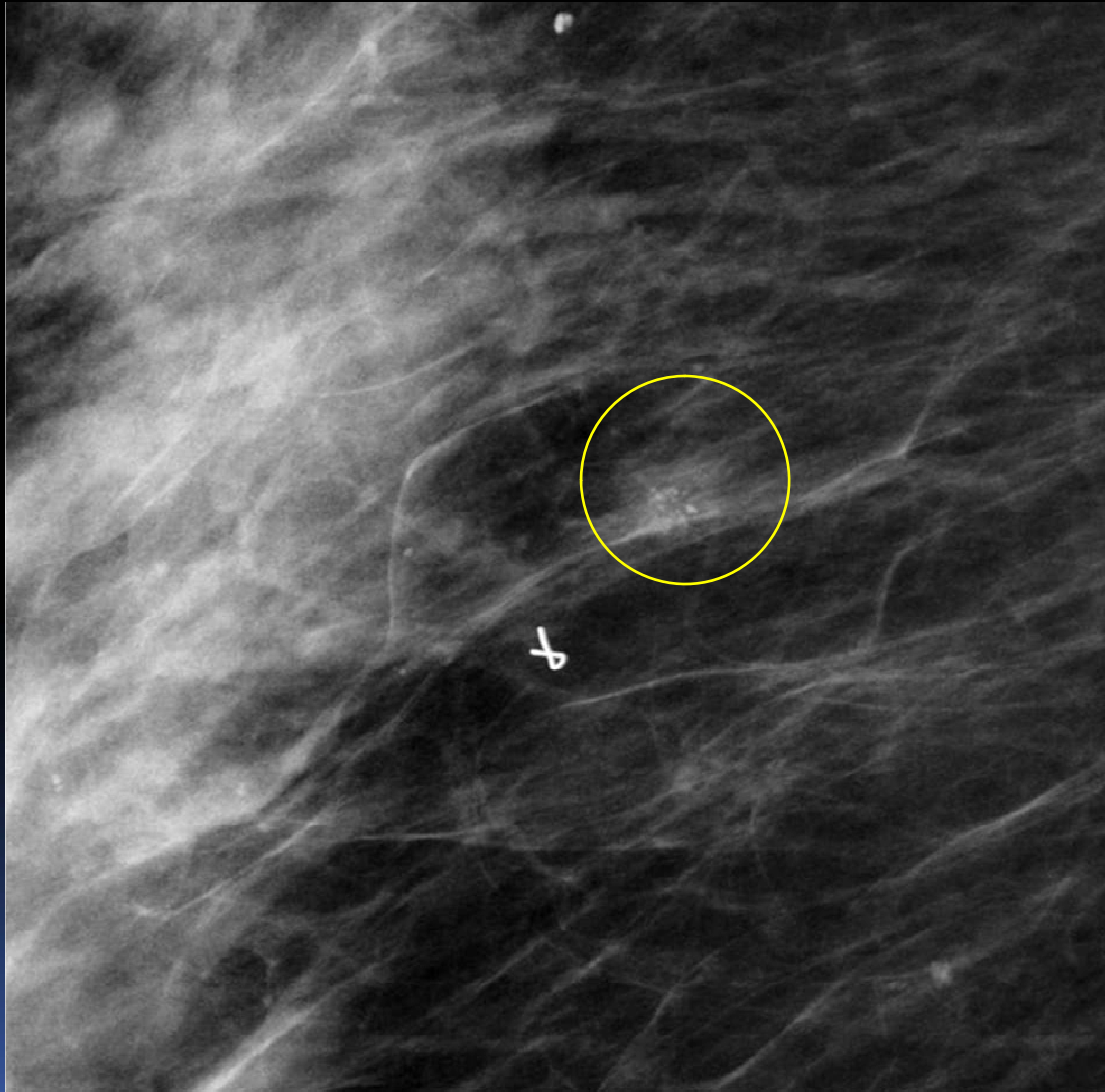


Fibroadenoma in
involuzione
calcifica



Controllo successivo

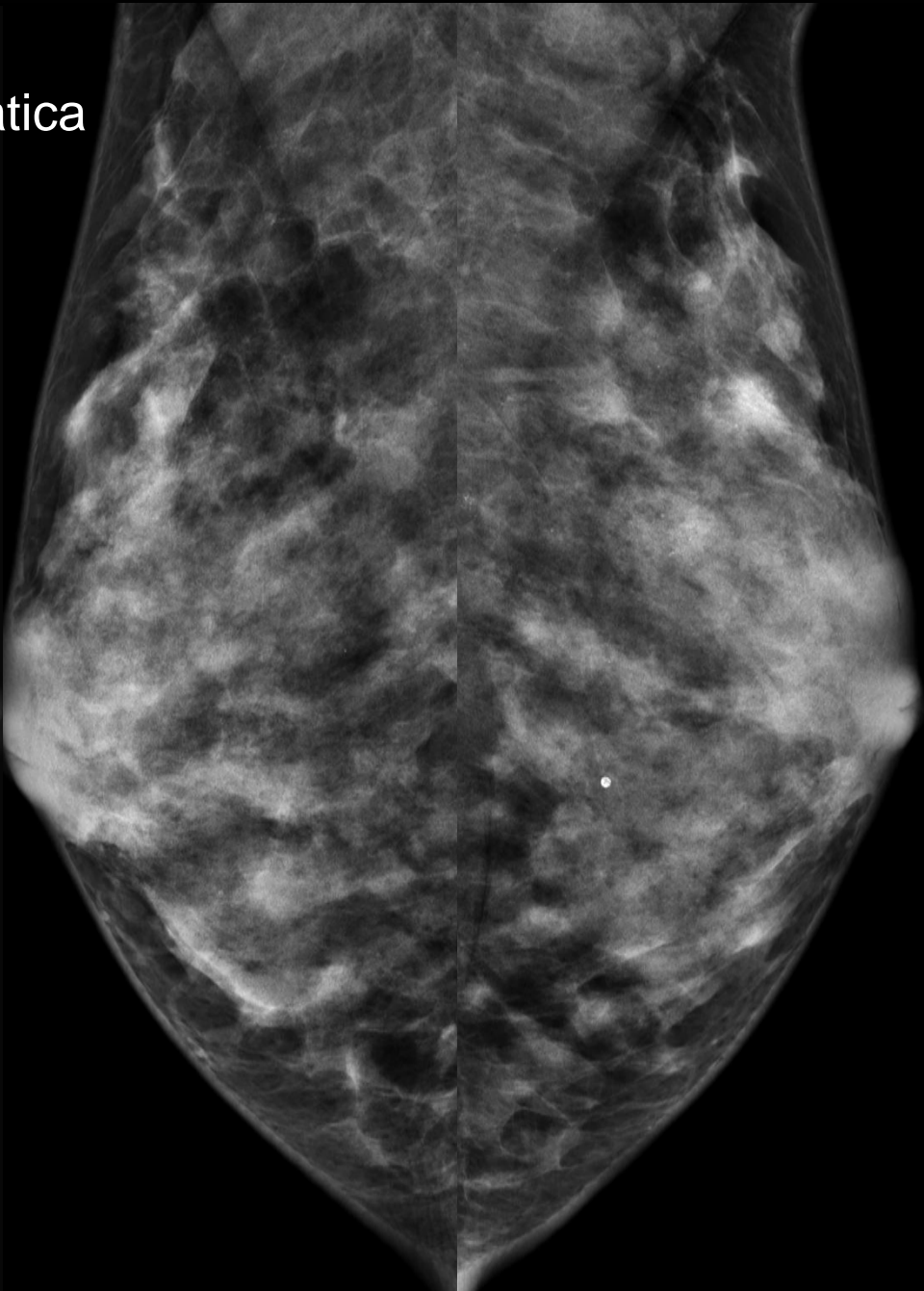
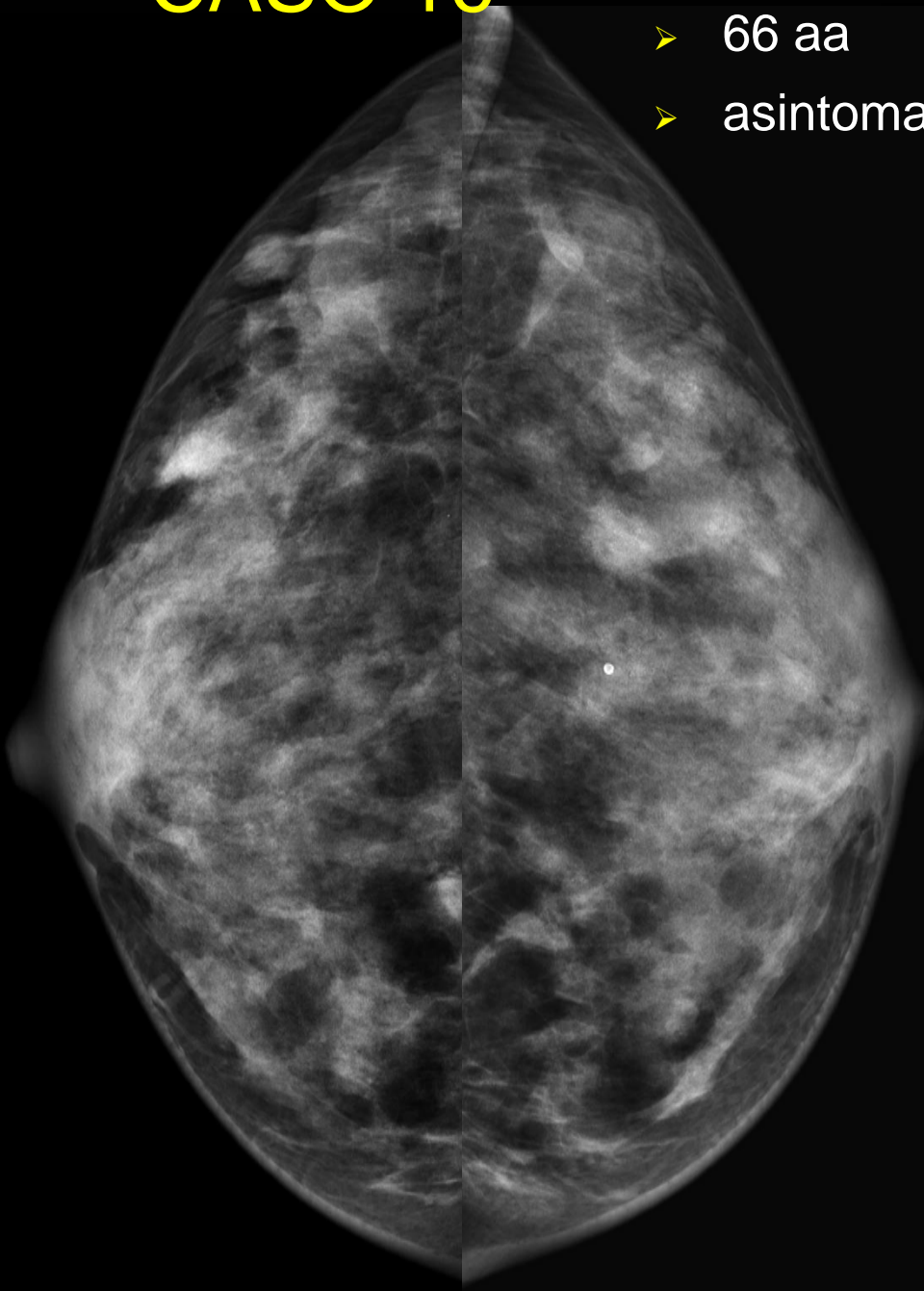


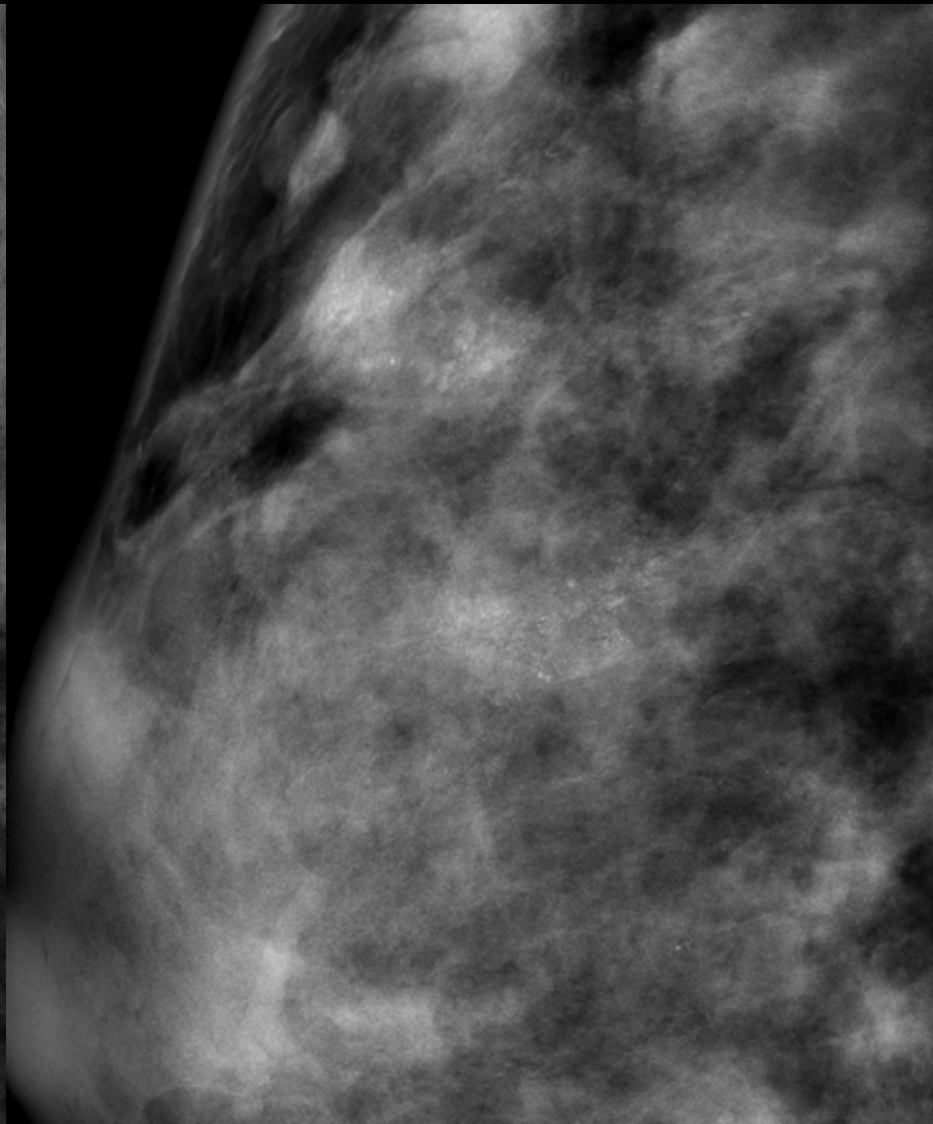
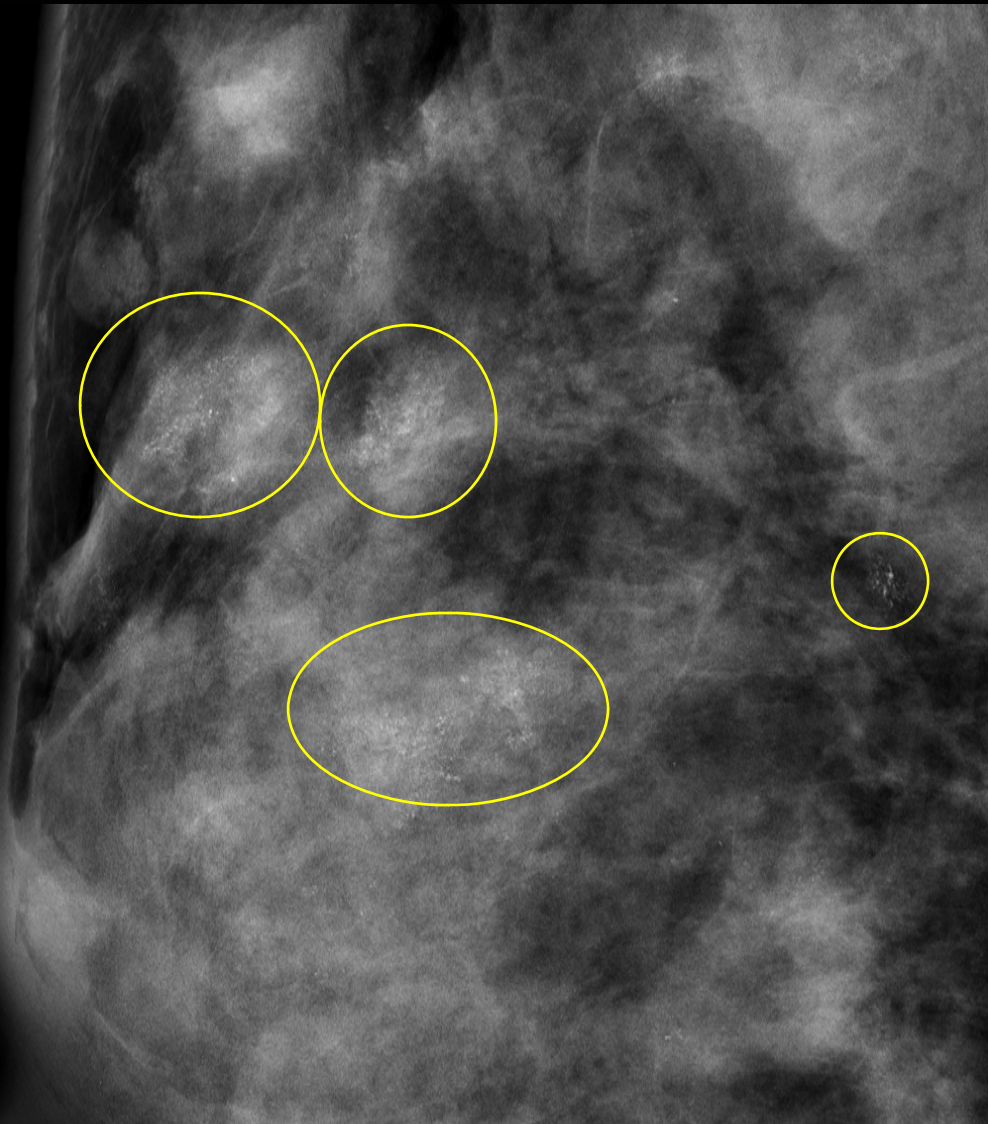


DCIS cribriforme,
G2

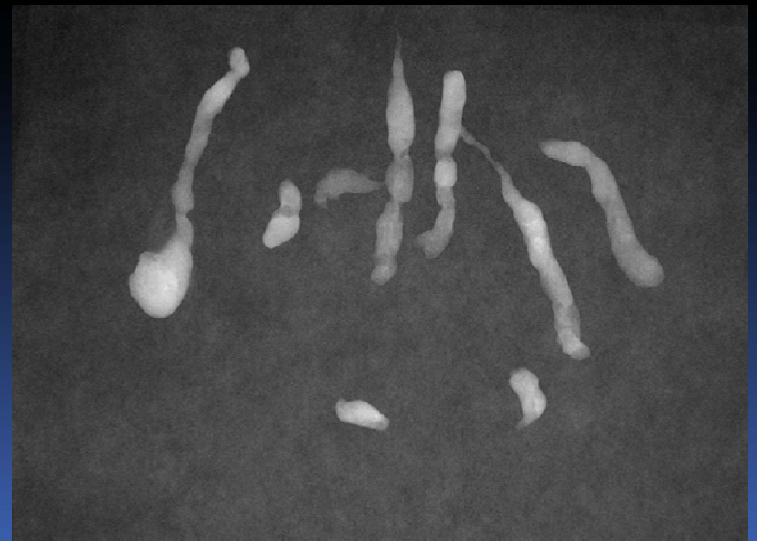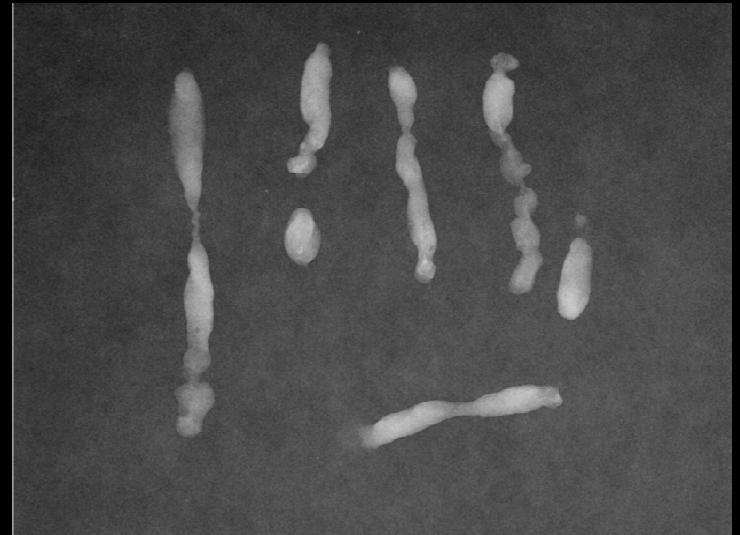
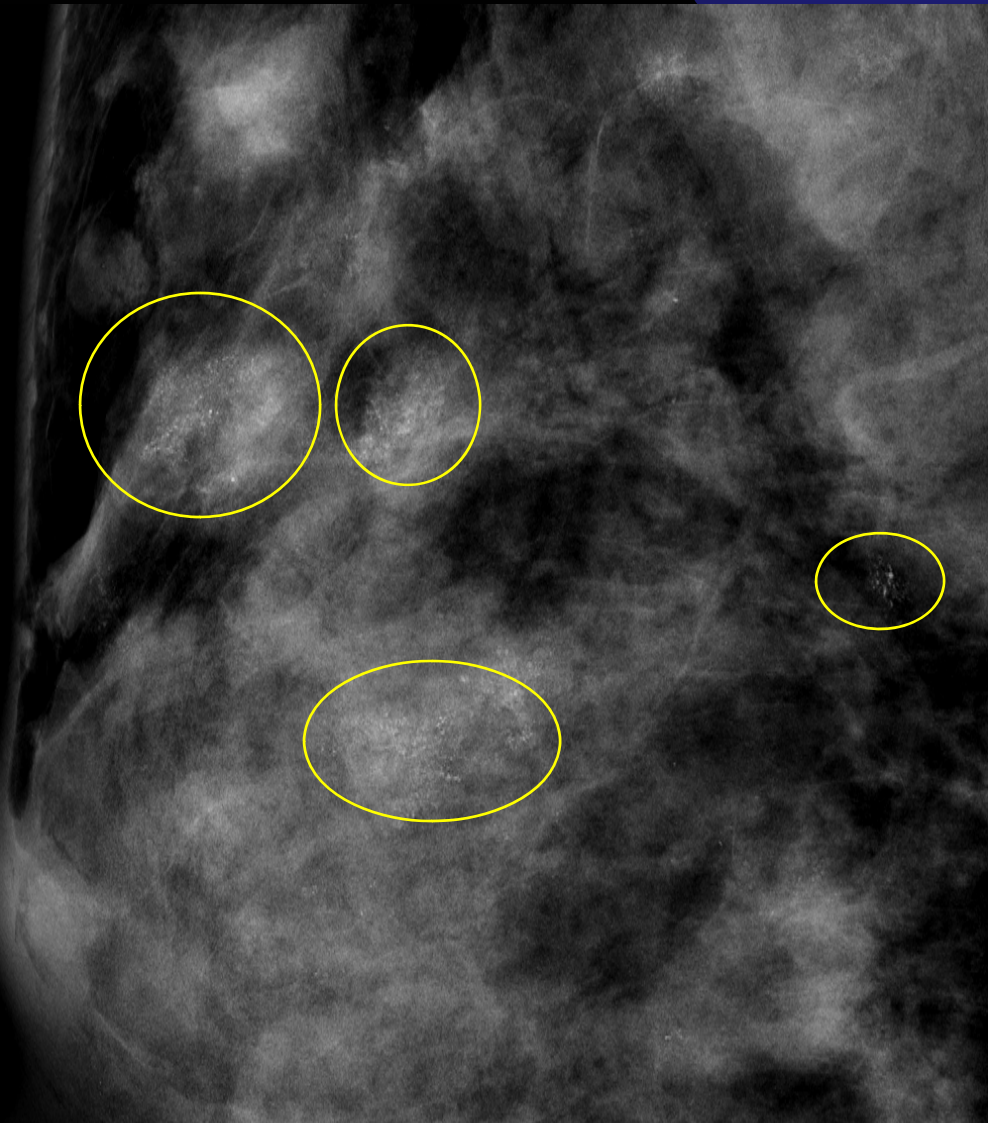CASO 16

- 66 aa
- asintomatica

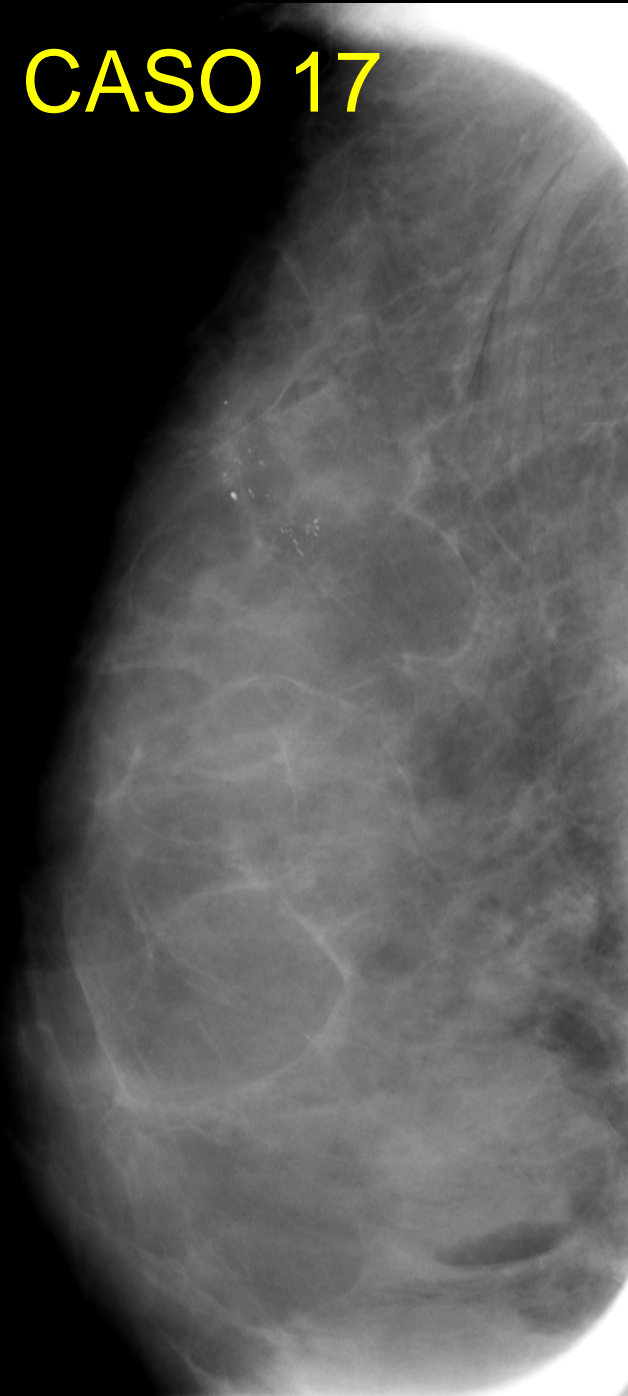




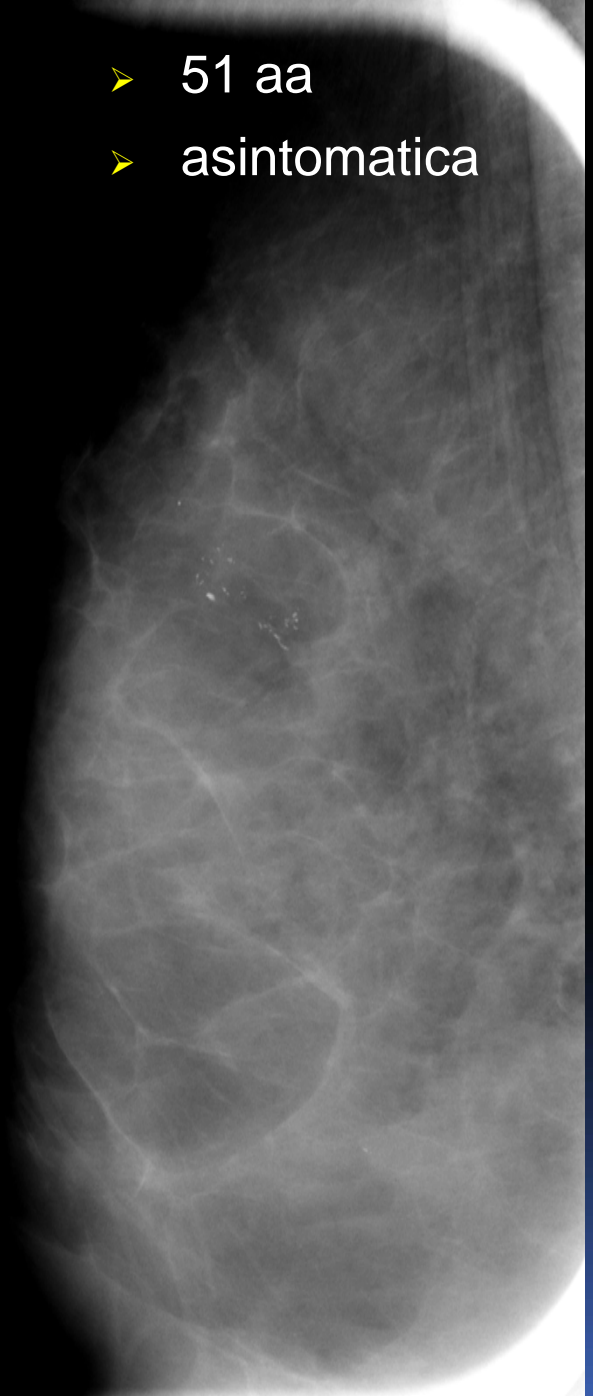
Mastopatia fibrocistica con deposizioni calcifiche



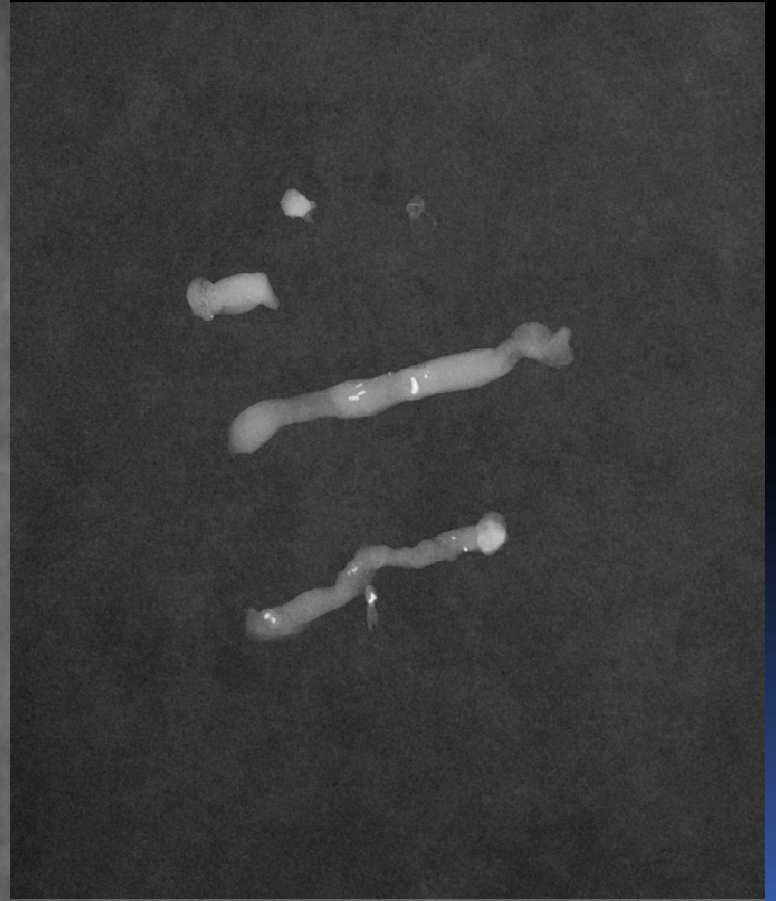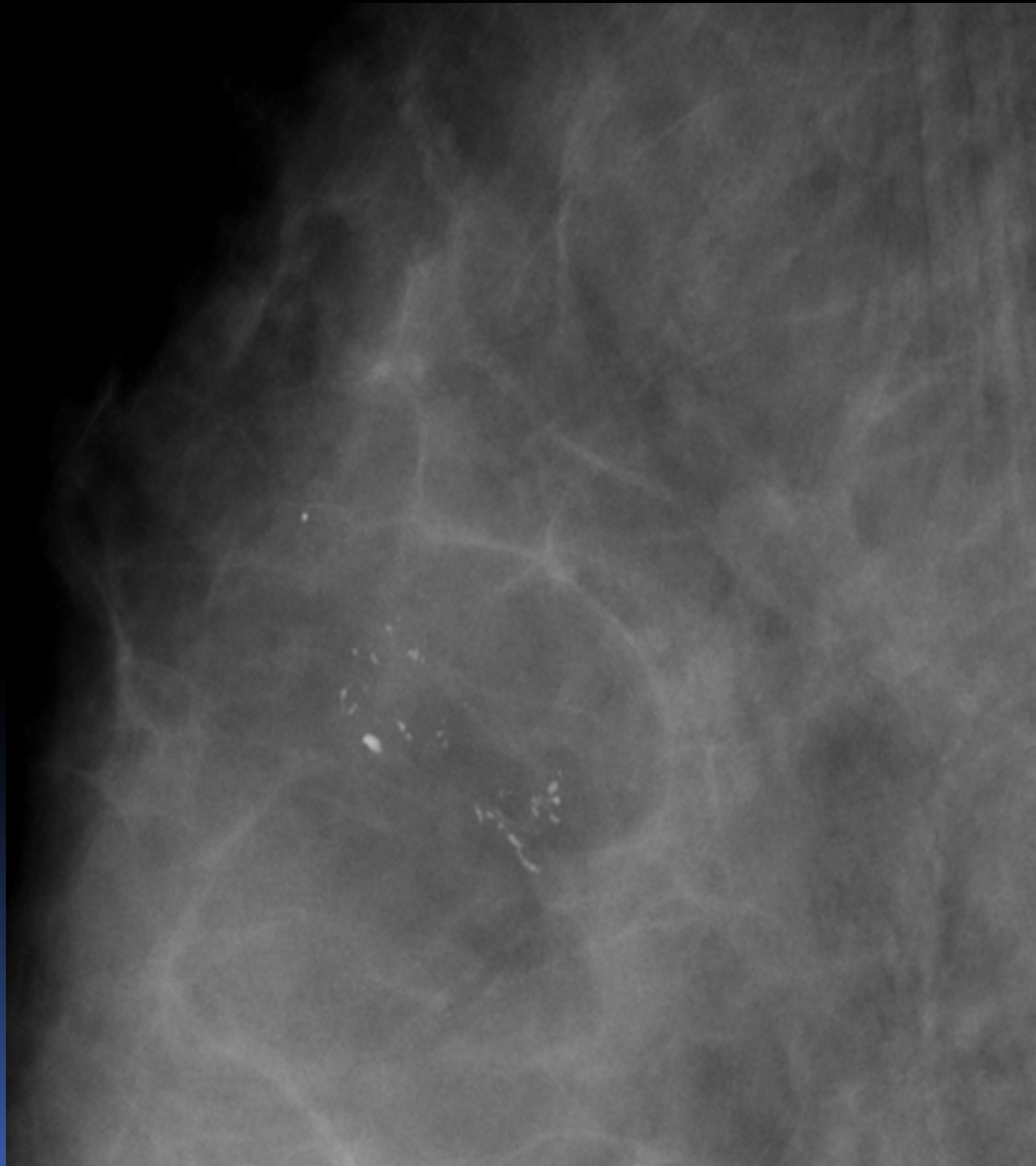
CASO 17



- 51 aa
- asintomatica

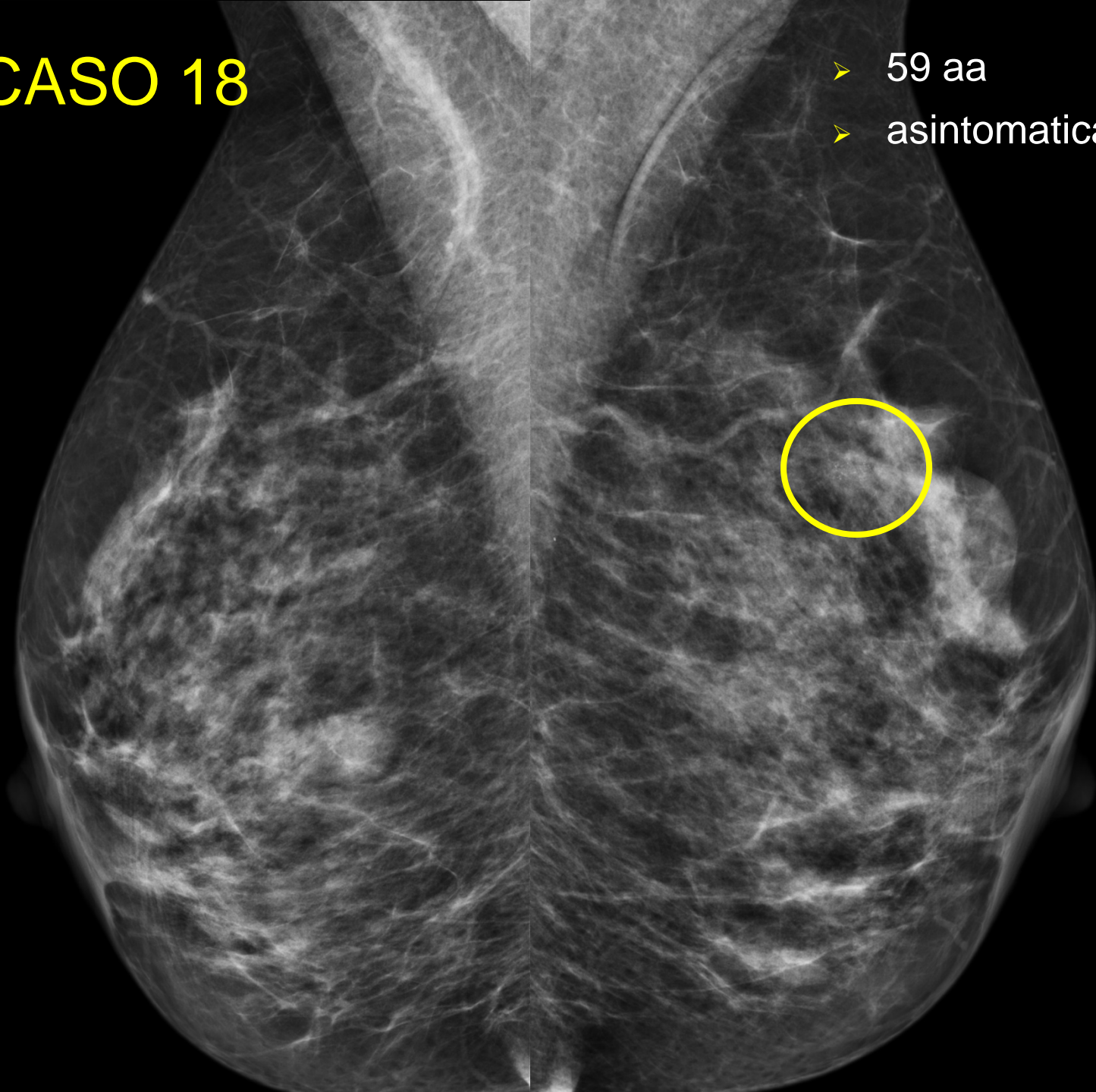


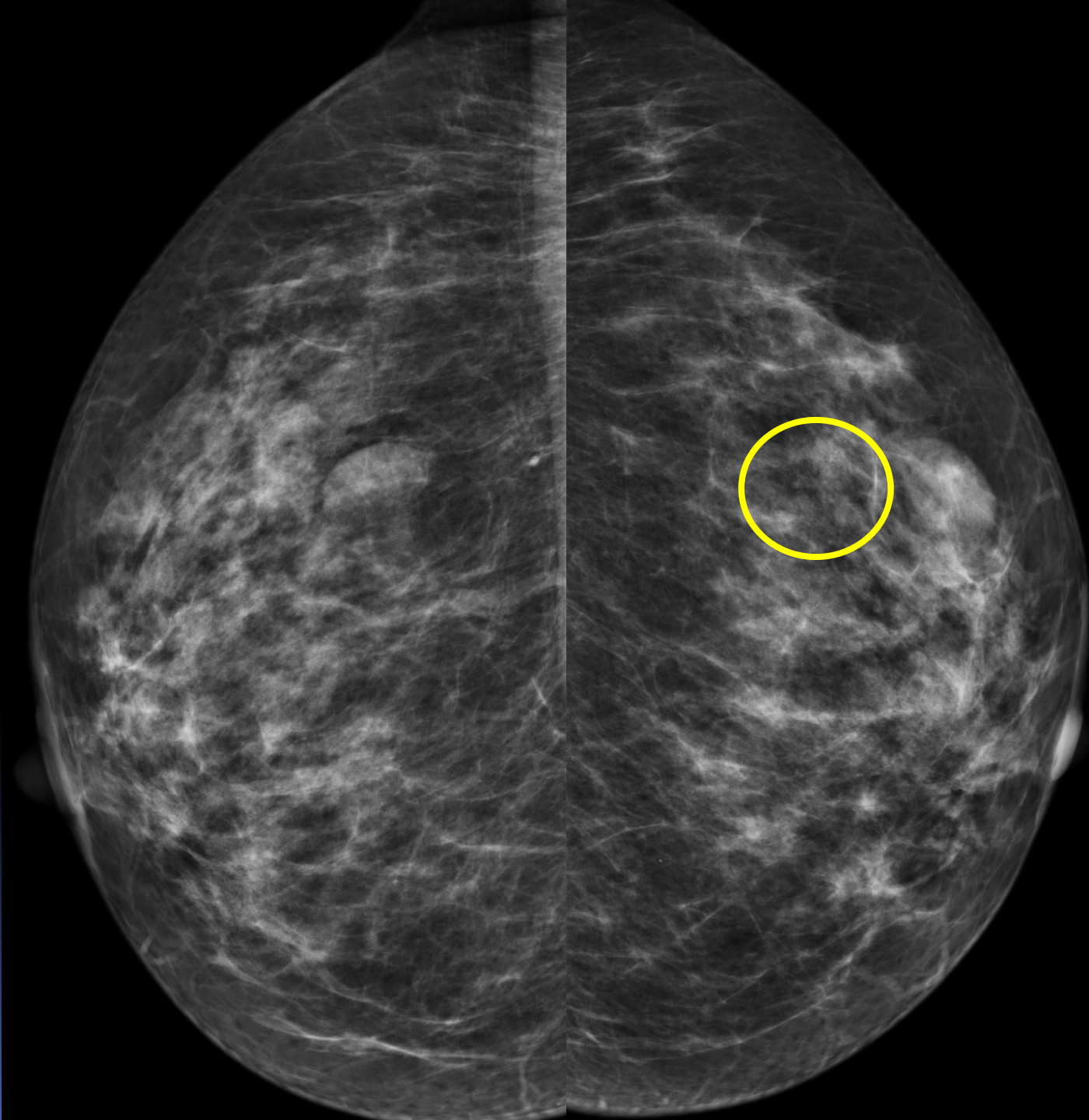
DCIS solido e
cribriforme
G2

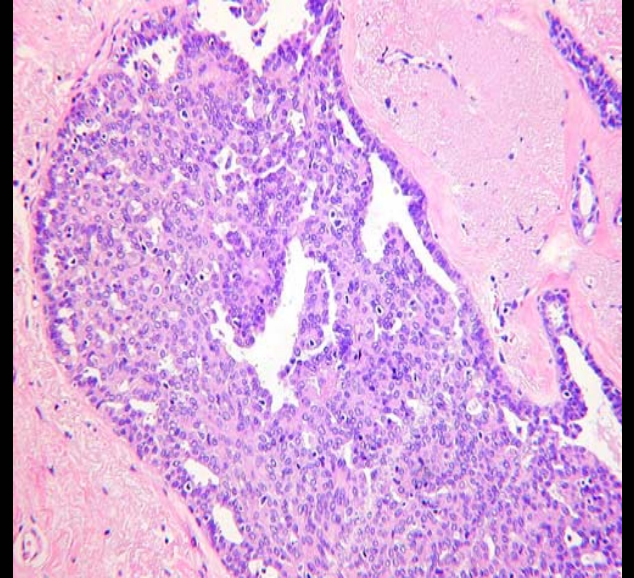
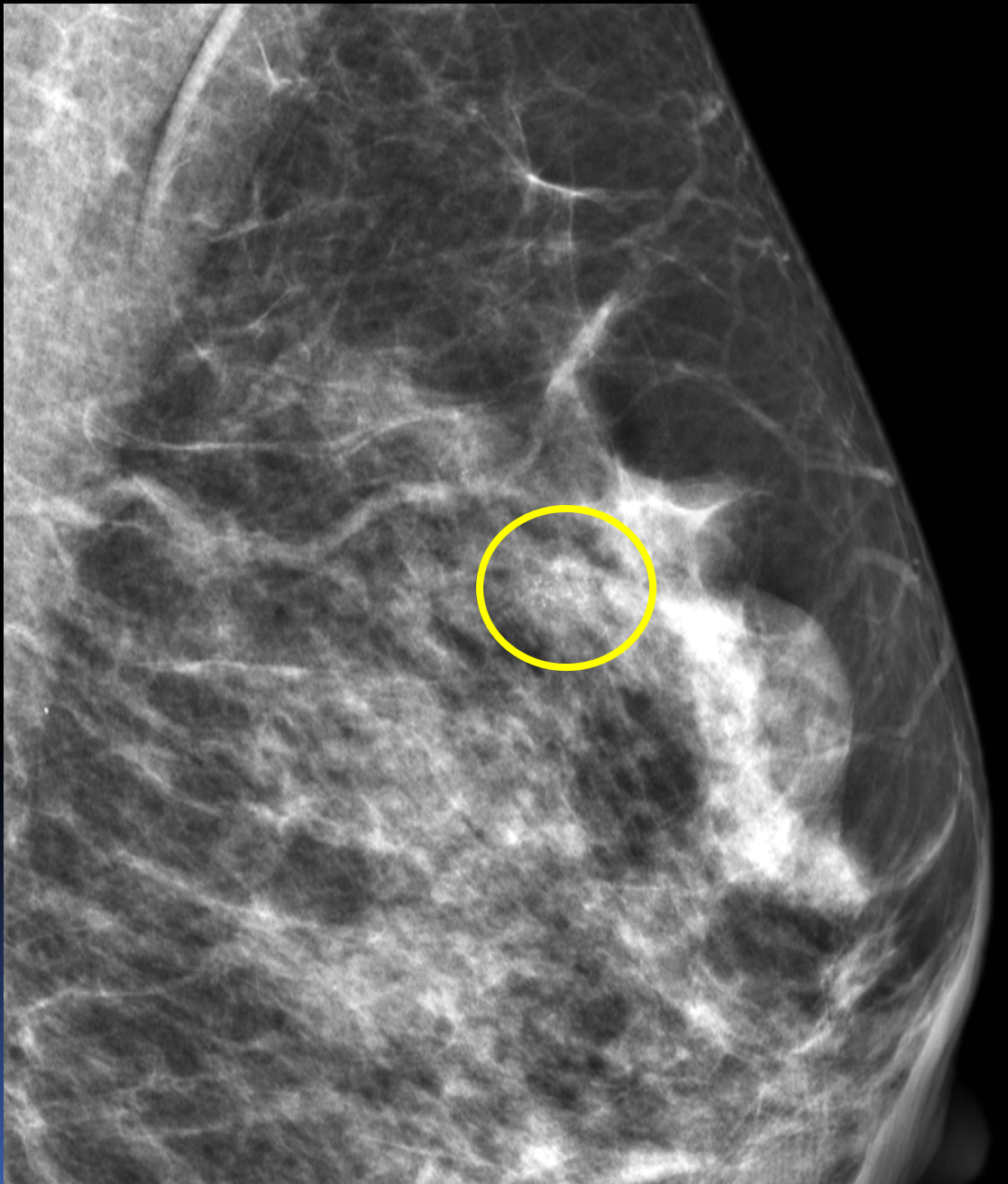


CASO 18

- 59 aa
- asintomatica



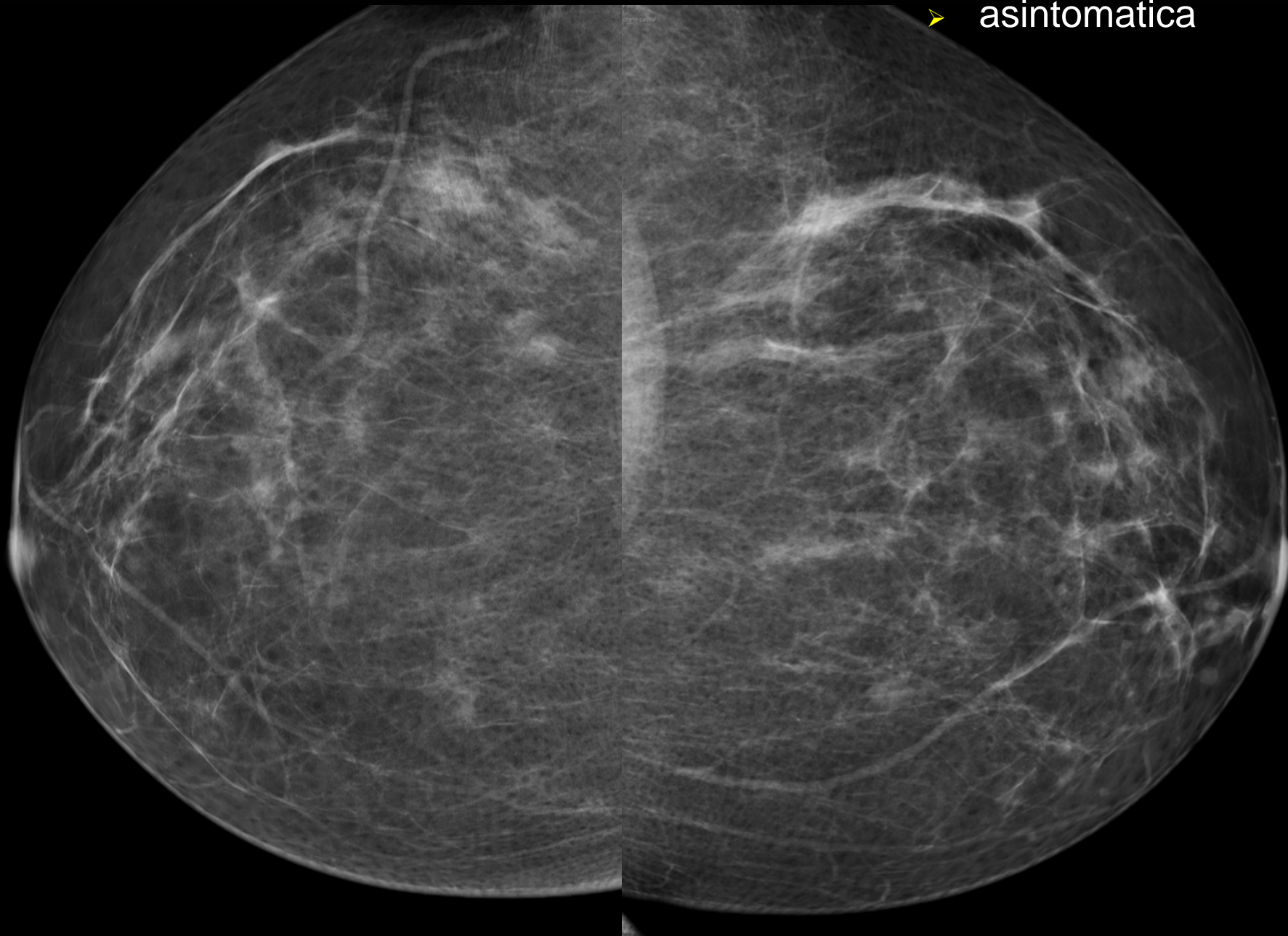

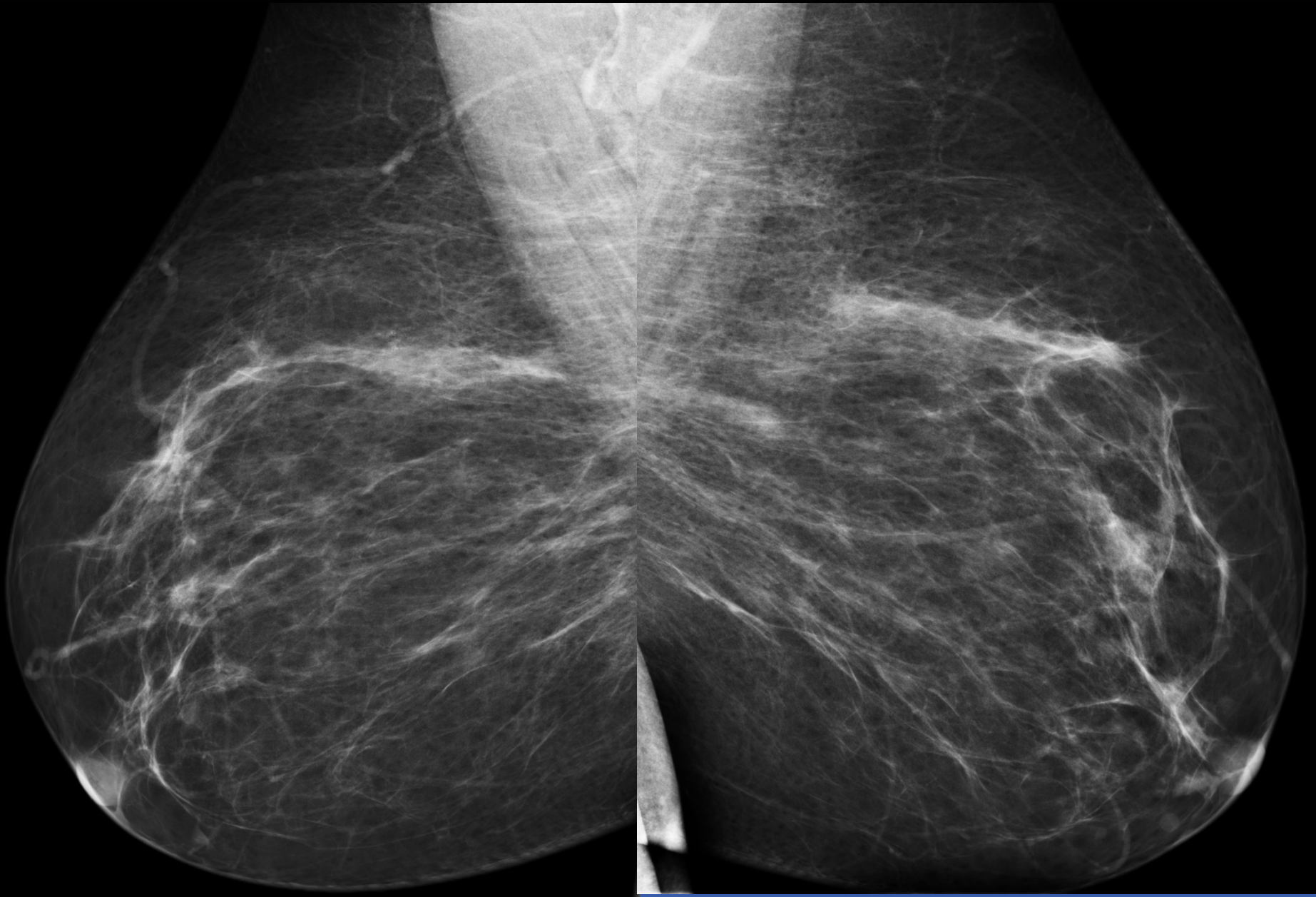


Iperplasia
epiteliale atipica,
di basso grado,
tipo colonnare,
con deposizioni
calcifiche

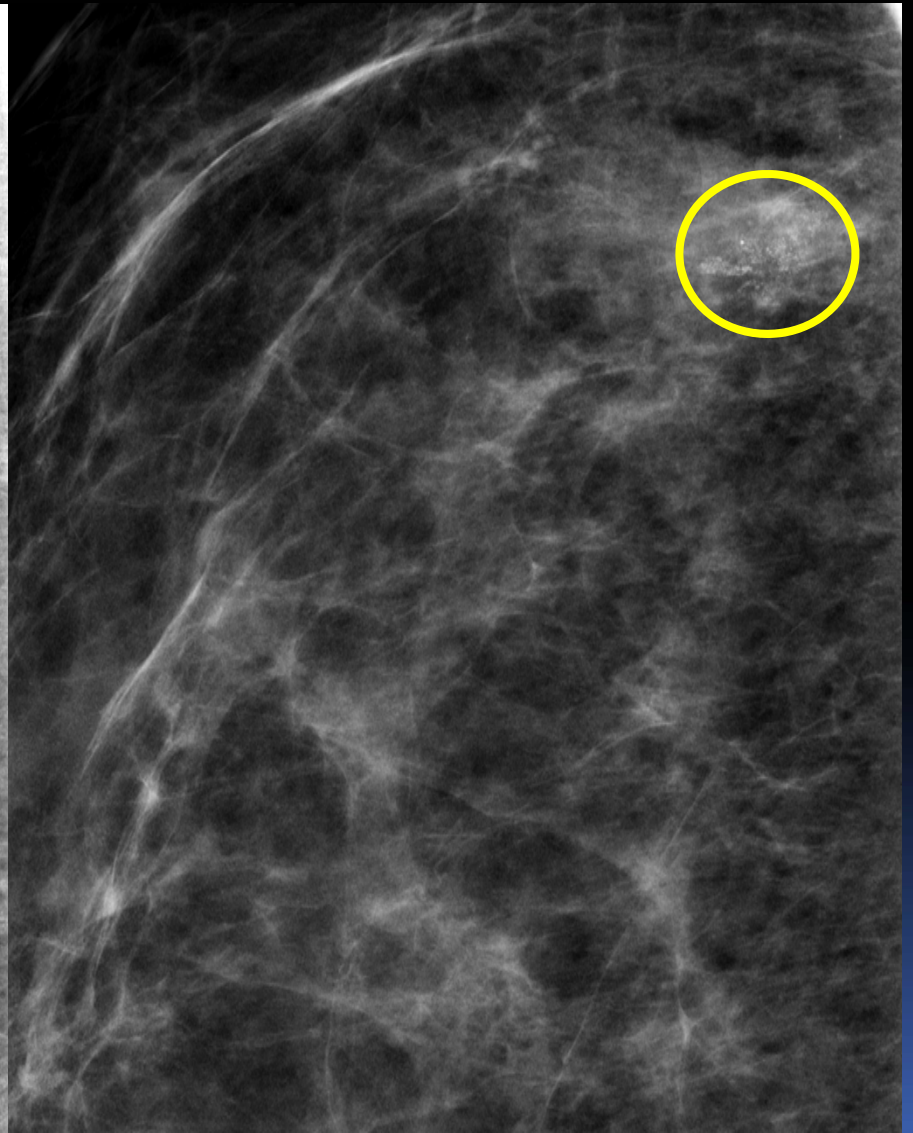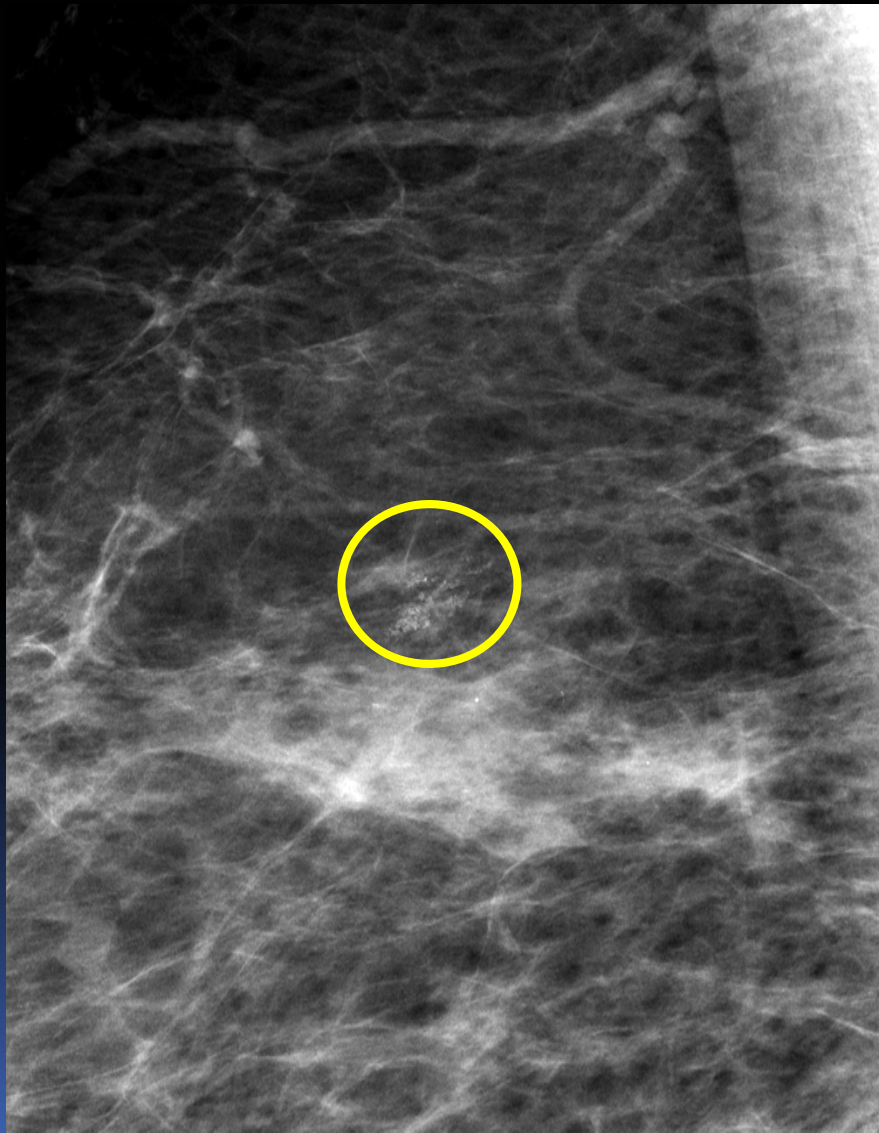
CASO 19

- 59 aa
- asintomatica





Adenosi
e
blunt ductal adenosis con microcalcificazioni



CASO 20

- 50 aa
- asintomatica
- mastoplastica riduttiva



